



The Open Dentistry Journal

Content list available at: <https://opendentistryjournal.com>



SYSTEMATIC REVIEW

Facial Asymmetry Detected with 3D Methods in Orthodontics: A Systematic Review

Laura Pedersoli¹, Domenico Dalessandri¹, Ingrid Tonni¹, Marino Bindi^{2,*}, Gaetano Isola³, Bruno Oliva¹, Luca Visconti¹ and Stefano Bonetti¹

¹Department of Medical and Surgical Specialties, Radiological Sciences, and Public Health, School of Dentistry, University of Brescia, Brescia, Italy

²Dental Clinic, A.O.U. Maggiore della Carità di Novara, Novara, Italy

³Department of General Surgery and Medical and Surgical Specialties, School of Dentistry, University of Catania, Catania, Italy

Abstract:

Background:

Historically, the development of two-dimensional (2D) imaging techniques forerun that of three-dimensional (3D) ones. Some 2D methods are still considered valid and effective to diagnose facial asymmetry but 3D techniques may provide more precise and accurate measurements.

Objective:

The aim of this work is to analyze the accuracy and reliability of the imaging techniques available for the diagnosis of facial asymmetry in orthodontics and find the most reliable.

Methods:

A search strategy was implemented using PubMed (National Library of Medicine, NCBI).

Results:

A total of 3201 papers were identified in electronic searches. 90 articles, available in full text, were included in the qualitative synthesis consisting of 8 reviews on the diagnosis of facial asymmetry, 22 *in vivo* and *in vitro* studies on 2D methods and 60 *in vivo* and *in vitro* studies on 3D methods to quantify the asymmetry.

Conclusion:

2D techniques include X-ray techniques such as posterior-anterior cephalogram, which still represents the first level exam in the diagnosis of facial asymmetry. 3D techniques represent the second level exam in the diagnosis of facial asymmetry. The most current used techniques are CBCT, stereophotogrammetry, laser scanning, 3D optical sensors and contact digitization. The comparison between bilateral parameters (linear distances, angles, areas, volumes and contours) and the calculation of an asymmetry index represent the best choices for clinicians who use CBCT. The creation of a color-coded distance map seems to represent the most accurate, reliable and validated methods for clinicians who use stereophotogrammetry, laser scanning and 3D optical sensors.

Keywords: Facial asymmetry, Orthodontics, Diagnosis, 2D diagnosis, 3D diagnosis, Three-dimensional techniques.

Article History

Received: May 30, 2021

Revised: August 5, 2021

Accepted: October 27, 2021

1. INTRODUCTION

Clinically, “symmetry” is synonymous with balance, while “asymmetry” refers to a difference between homologous ele-

ments in which the harmonic relationship among structures is altered [1]. The observation of facial or dental asymmetry in patients, both mild or severe, is a common and important finding. It is frequent because perfect symmetry of the body is extremely rare and primarily it remains a theoretical concept. It is important because most recent anthropological researches reveal that symmetry is fundamental in order to increase the charm of human face [1 - 5].

* Address correspondence to this author at the Dental Clinic, A.O.U. Maggiore della Carità di Novara, Viale Piazza d'Armi n. 1 - 28100 Novara, Italy; Tel: +39 3213734948; Fax: +39 3213734843; E-mail: marino.bindi@maggioreosp.novara.it

Literature lacks a comprehensive definition of facial asymmetry [6 - 12]. According to Bishara [6], for example, it corresponds to “differences in the size or relationship between the two sides of the face”. According to Beyer [8], it is “a lack of coincidence between maxillary and mandibular midlines as well as the facial soft-tissues midlines”. Kwon [12] claims that patients with facial asymmetry are distinguished by a chin deviation greater than 4 mm from the facial midline.

Epidemiological studies estimated that facial asymmetry in orthodontic patients has a prevalence of around 12 to 37% in the USA [13 - 15], 23% in Belgium [16], and 21% in Hong Kong [17] if the diagnosis is clinical. On the other hand, if the diagnosis is based on radiological findings, the prevalence may exceed 50% [18, 19].

Regarding the diagnosis, there are multiple methods available for clinicians to identify and assess facial asymmetry [5, 10, 11, 20 - 24]. Historically, the development of two-dimensional (2D) imaging techniques, such as panoramic radiographs, posterior-anterior cephalograms and photographs, forerun that of three-dimensional (3D) ones, which included CBCT, stereophotogrammetry, laser scanning and contact digitalization [22]. 3D techniques represent a fundamental advancement for improving our knowledge of facial asymmetry [25], and they may provide more precise and accurate measurements [22]. However, some 2D methods are still considered valid and effective in diagnosing facial asymmetry [22].

Each method varies in accuracy, reliability, biologic and economic costs. Furthermore, it is important to identify the most appropriate diagnostic tool for each clinical case, as errors during the diagnostic phase could lead to misinterpretation of the asymmetry and they may limit treatment options. Therefore, the aim of the present review was to analyze the accuracy and reliability of the imaging techniques available for the diagnosis of facial asymmetry in orthodontics and find the most reliable.

2. MATERIALS AND METHODS

A literature search with “facial asymmetry”, “diagnosis”, “2D diagnosis” and “3D diagnosis” keywords was conducted on PubMed (National Library of Medicine, NCBI) on articles published from 1994 to 2020 in English and in Italian and available in full text (last access on 30th April 2020). This restricted time span was chosen considering that, with the rapid technological evolution of diagnostic instruments, a greater homogeneity of analyzed tools that are still in use is more suitable for finding useful suggestions for contemporary practice compared to a broader historic review. These studies concern facial and/or mandibular asymmetry (not regarding more limited investigation field like, for example, condylar asymmetry only), they have been performed on patients or cadavers and they present detailed documentation relating to the selection of subject, image processing and calculations performed to quantify asymmetry.

Therefore, the various methods used to diagnose facial asymmetry were extrapolated. Another database search was performed using “clinical examination”, “panoramic radiograph”, “posterior-anterior cephalometry”, “digital photography”, “CB-CT”, “stereophotogrammetry”, “laser scanning”, “3D optical sensor” and “contact digitalization” keywords. Subsequently, the terms of the second search were combined with the first ones in order to reduce irrelevant results and finally the bibliographies of the extrapolated studies were analysed in order to offer the widest possible overview of the available methods.

3. RESULTS

3.1. Study Selections

The initial research led to the identification of 3201 articles, the majority of which were excluded after reading the abstracts because they were not relevant to the topic of this study or inaccessible. 90 articles, available in full text, were included in the qualitative synthesis, which consisted of 8 reviews [5, 6, 10, 24 - 28] on the diagnosis of facial asymmetry, 22 *in vivo* and *in vitro* studies on 2D methods and 60 *in vivo* and *in vitro* studies on 3D methods for quantifying asymmetry. The articles selection process is illustrated through the PRISMA flow diagram presented in Fig. (1).

3.2. Results of Studies

Clinical examination shows the presence of sagittal, coronal and vertical asymmetry and is divided into an extra-oral and an intra-oral examination [10, 11, 22 - 24, 26]. To enhance asymmetry investigation clinicians can use two and three-dimensional techniques.

3.3. Two-Dimensional Techniques

Two-dimensional techniques, summarized in Table 1, include radiological techniques such as posterior-anterior cephalogram (PA cephalogram), which still represents the first level exam in the diagnosis of facial asymmetry, panoramic radiography (OPG) and submentovertex projection [5, 6, 11, 22, 24, 29]. The latter is no longer used in the daily routine because it exposes patient’s thyroid to an important dose of radiations, it forces the patient to assume an uncomfortable position during the examination and there is the superimposition of different anatomical structures that result in a lower accuracy compared to other methods [22, 27]. OPG is also rarely used for this objective in clinical practise as it is affected by many disadvantages like distortion and magnification of radiographed structures and limitation of diagnosis to condyle and mandibular ramus asymmetry [22, 27, 28]. Digital photography represents a valid two-dimensional non-radiographic technique for the diagnosis of facial asymmetry [29, 30]. It completes the clinical evaluation and makes it more accurate. The frontal view is the most useful to analyses patient’s asymmetry [5, 22].

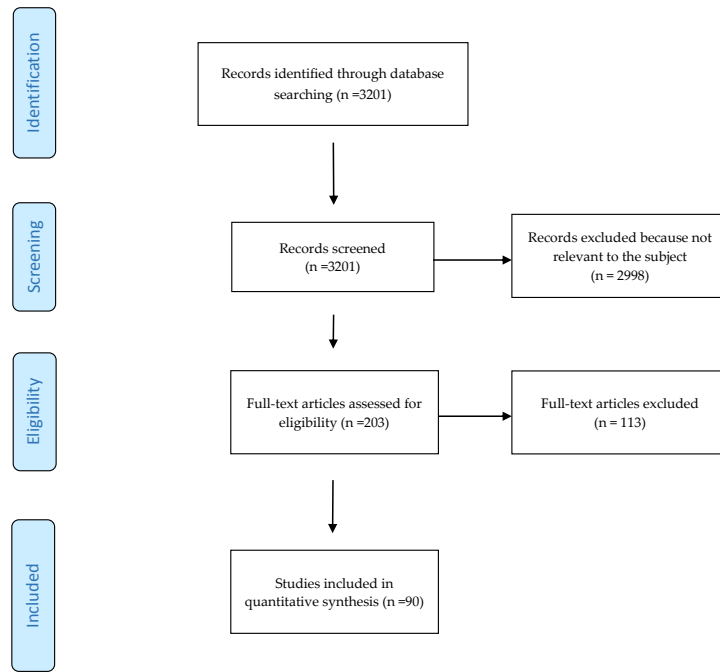


Fig. (1). PRISMA flow diagram of the review.

Table 1. Overview of included studies quantifying the asymmetry by means of two-dimensional techniques.

Study	Techniques Used	Use of Reference Lines	Number of Landmarks	Methods to Quantify the Asymmetry	Aim of the Study
Altug-Atac (2008)	PA cephalogram and digital photography	Yes	13	Comparison between bilateral distances	To investigate the relationship between soft-tissue and underlying skeletal structures before and after unilateral mandibular distraction osteogenesis
Baudouin (2004)	Digital photography	Yes	53	Calculation of an asymmetry index (linear)	To investigate female facial attractiveness by comparing the ratings made by male judges with the metric characteristics of female faces
Danel (2007)	Digital photography	No	2	Comparison between left and right part of eye-mouth-eye angle	To test the hypothesis that men with more masculine values of EME angle and/or more symmetrical values would be perceived by women as more attractive
Edler (2001)	Digital photography	No	6	Comparison between areas, perimeters and moments of the inferior half-face	To investigate assessment of mandibular asymmetry by clinicians and to evaluate a new computerized system
Edler (2003)	PA cephalogram and Digital photography	No	4	Comparison between bilateral areas, perimeters, compactness (shapes) and moments of the inferior third of face	To assess asymmetry analysis of PA radiographs as a method for mandibular asymmetry measurement and to compare it with the digitization of mandibular outlines from facial photographs
Ercan (2008)	Digital photography	(Yes)	42	Calculation of Euclidean distance matrix analysis*	To quantify asymmetry between the right and the left parts of the face
Eskelsen (2009)	Digital photography	Yes	2	Evaluation of coincidence or not between bipupillar bisector line and dental midline	To analyze the axial symmetry between the bipupillar midline and the maxillary central incisors midline
Fong (2010)	PA cephalogram	Yes	14	Comparison between bilateral distances to reference lines	To investigate the facial skeletal features associated with chin deviation
Good (2006)	Lateral cephalogram and Digital photography	Yes	10	Comparison between bilateral areas, perimeters, compactness (shapes) and moments of the inferior third of face	To investigate the relationship between mandibular outline asymmetry and skeletal discrepancy

(Table 1) contd.....

Study	Techniques Used	Use of Reference Lines	Number of Landmarks	Methods to Quantify the Asymmetry	Aim of the Study
Gosla-Reddy (2011)	Digital photography	Yes	Not well defined	Comparison between areas, bilateral distances and angles	To assess and compare nasal symmetry in patients who underwent correction of a complete unilateral cleft lip
Grammer (1994)	Digital photography	No	13	Calculation of an asymmetry index (linear)	To investigate if men and women prefer averageness and symmetry in faces
Haraguchi (2002)	PA cephalogram and Digital photography	Yes	7	Comparison between landmarks' bilateral distances to the reference lines, subjective assessment of asymmetry	To investigate the frequency, site, amount, and direction of facial asymmetry in human adults with mandibular prognathism and examined if these characteristics were associated postnatally with cardinal clinical signs that may indicate a predisposition to facial asymmetry
Hwang (2007)	PA cephalogram and Digital photography	Yes	11	Evaluation of seven measurements (bilateral distances, angles) on PA cephalogram and one on digital photography	To classify patients with facial asymmetry by using the cluster analysis
Kjellberg (1994)	Panoramic radiograph	No	6	Comparison between bilateral distances and "condylar ratio"	To develop and apply a reliable method of measuring the effects of condylar lesions quantitatively on panoramic radiographs
Nakamura (2001)	PA cephalograms and Digital photography	Yes	18	Calculation of an asymmetry index (linear)	To compare the asymmetry of the facial skeleton or expression of such patients with those of healthy subjects
Penton-Voak (2001)	Digital photography	No	14	Ratings of similarity between mirrored faces, evaluation of horizontal/vertical asymmetry from x-y coordinates of bilateral points, digital averages (composite) of multiple individual faces	To demonstrate that symmetric faces are more attractive than less symmetric ones
Rikowsky (1999)	Videocamera (snapshots that showed the best positions)	No	13	Calculation of an asymmetry index (linear)	To compare ratings of body odor, attractiveness, and measurements of facial and body asymmetry
Saglam (2004)	Panoramic radiograph	No	4	Calculation of an asymmetry index (linear)	To examine the relation of condylar asymmetry index in dentate patients with TMD
Scheib (1999)	Digital photography	Yes	14	Calculation of an asymmetry index (linear)	To examine women's perception of facial attractiveness and symmetry
Trpkova (2003)	PA cephalogram	Yes	44	Comparison between landmarks' bilateral distances to the reference lines	To determine the ability of various horizontal and vertical reference lines to provide measurements of dentofacial asymmetries from PA cephalograms
Yamashita (2009)	PA cephalogram and digital photography	Yes	9	Comparison between bilateral landmarks' distances to reference lines, comparison between areas	To examine labial asymmetry in patients with jaws' deformity and facial asymmetry
Yu (2009)	Digital photography	Yes	7	Calculation of an asymmetry index (angular)	To determine whether the technique used in the study can improve the midline symmetry of facial soft tissues

3.4. Three-Dimensional Techniques

In respect of 3D radiographic techniques, clinicians use cone-beam computed tomography (CBCT) to evaluate asymmetry creating three-dimensional virtual models from it [12, 31 - 33]. Stereophotogrammetry, laser scanners, 3D optical sensors and contact digitalization represent the 3D non-radiographic counterparts [34 - 36]. Table 2 presents an overview of studies quantifying the asymmetry through 3D techniques.

Cone-beam images are not characterized by tissues and

organs superimposition and allow the exact definition of structures in three dimensions [22]. The patient positioning during the examination is critical in this technique as well as in other 3D and 2D ones [37].

Stereophotogrammetry is used in measuring two or more photographic images taken from different positions in order to realize a 3D reconstruction of his/her facial soft tissues according to a stereoscopic vision using triangulation concepts [38 - 40]. The outcome is a sort of scan (but without the use of scanner) of the patient's face. This technique affords obtaining a precise and realistic rendering of the facial surface [34, 41].

Table 2. Overview of included studies quantifying the asymmetry by means of three-dimensional.

Study	Techniques Used	Use of Reference Planes	Number of Landmarks	Methods to Quantify the Asymmetry	Aim of the Study
Al-Rudainy (2018)	Stereo-photogrammetry	Yes	25	Creation of a color-coded map (based on absolute distances between original and mirrored images superimposed)	To evaluate facial asymmetry before and after surgical repair of cleft lip in infants
Alqattan (2015)	Laser scanning	Yes	21	Calculation of a landmark-based asymmetry index (according to Huang) and carrying out a surface-based asymmetry analysis with the creation of mirrored images	To collect the reference values for facial asymmetry in adults using landmark and surface-based three-dimensional analyses and to compare their diagnostic abilities
An (2017)	CBCT	Yes	11	Calculation of the horizontal distance from the reference planes to menton and ANS and the angles between the reference planes and the line passing through ANS and PNS	To compare eight candidate midsagittal planes constructing from different median landmarks to determine the most appropriate one for evaluating craniofacial asymmetry
Baik (2010)	Laser scanning	Yes	31	Creation of a color-coded distance map based on the scans superimposed, evaluation of points coordinates changes (69 linear, 8 angular, 13 proportional measurements)	To use a 3D laser scanner to evaluate the soft-tissue changes after the correction of skeletal Class III malocclusions with orthognathic surgery
Benz (2002)	3D Optical sensor	Yes	2	Determination of the symmetry plane after registration between original and mirrored images	To present an application of optical metrology and image processing to oral and maxillofacial surgery
Berssenbrugge (2014)	Stereo-photogrammetry Digital photography	Yes	22	Calculation of 2D asymmetry index (according to Nakamura, Badouin and Grammer) and 3D asymmetry index (starting from the superimposition between original and mirrored images)	To compare three selected 2D analysis methods and one 3D analysis method
Bilwatsch (2006)	3D Optical sensor	Yes	25	Calculation of the distances of the landmarks from the plane of symmetry and in postero-anterior direction, comparison between virtual volumes of the face and angles	To assess the degree of facial asymmetry in patients suffering from unilateral cleft lip, alveolus and palate
Bugaighis (2014)	Stereo-photogrammetry	No	39	Calculation of the distances between each landmark and the matching reflected landmark	To explore 3D facial asymmetry differences in operated children with oral clefts and to compare the results with a control group
Cassi (2018)	Stereo-photogrammetry	Yes	16	Creation of a color-coded distance map (based on calculation of RMSE* on the original and mirrored images superimposed)	To quantify the surface of facial asymmetry in a group of young patients with hemifacial microsomia and to investigate differences with a homogeneous sample of healthy subjects
Cevidanes (2011)	CBCT	Yes	3	Creation of a color-coded distance maps (magnitude of the differences between the mirror and simulated asymmetry point-based models)	To determine if 3D shape analysis precisely diagnoses right and left differences in asymmetry patients
Claes (2011)	Stereo-photogrammetry	Yes	2	Creation of color-coded map based on distances between original and mirrored spatially-dense quasi-landmarks	To obtain robust and spatially-dense asymmetry assessments using a superimposition protocol for comparison of a face with its mirror image
Codari (2017)	Stereo-photogrammetry	No	29	Creation of a color-coded map of distances (based on calculation of RMSD ** on the original and mirrored images superimposed)	To present a new quantitative method to assess symmetry in different facial thirds

(Table 2) contd....

Study	Techniques Used	Use of Reference Planes	Number of Landmarks	Methods to Quantify the Asymmetry	Aim of the Study
Damstra (2011)	CBCT	Yes	21	Comparison between bilateral linear and angular measurements (including Hwang's ones), creation of a color-coded map based on distances between original and mirrored (midsagittal plane, half) images superimposed	To illustrate and discuss the method of mirror-image analysis in addition to the quantitative 3D analysis of asymmetry with a case report
Damstra (2012)	CBCT	Yes	40	Determination of the true midsagittal plane after superimposition of reflected models	To investigate if the cephalometric midsagittal planes using internal and midline structures are relevant to visible facial symmetry
Demant (2011)	Stereo-photogrammetry	No	22	Creation of a color-coded map based on distances between original and mirrored images superimposed	To investigate and compare facial asymmetry in subjects with JIA with unilateral, bilateral or no TM joint involvement
Djordjevic (2014), (2013)	Laser scanning	Yes	21	Creation of a color-coded map and an histogram to explain original shell-mirrored shell deviation, comparison between bilateral distances and angles	To explore facial symmetry in healthy growing individuals and determine whether asymmetric changes occur during adolescent growth
Economou (2018)	CBCT Stereo-photogrammetry	Yes	38	Comparison between bilateral distances to the reference planes and between bilateral gonial angles	To assess the correlation between facial hard and soft tissue asymmetry in patients with juvenile idiopathic arthritis, to identify valid soft tissue points for clinical examination, and to assess the smallest clinically detectable level of dentofacial asymmetry
Ekrami (2018)	Laser scanning	No	19	Creation of a color-coded map (based on distances between original and mirrored spatially-dense quasi-landmarks)	To perform a simulation study to illustrate the performance and benefit of spatially dense and automated approach in calculating fluctuating asymmetry over the traditional use of sparse landmarks
Ferrario (2003)	Contact digitalization	No	11	Calculation of linear distances, angular measurements, areas and volumes	To measure the difference between adult patients operated on for cleft lip and palate and healthy adults in an attempt to provide a final assessment of the facial outcome of surgery
Hajeer (2004)	Stereo-photogrammetry	No	19	Comparison between the patient's original configuration and the symmetrical one	To assess the magnitude of 3D asymmetry of facial soft tissues before and after orthognathic operations
Hartmann (2007)	3D Optical sensor	Yes	None	Determination of the symmetry plane (starting from the superimposition between original and mirrored images) and creation of a color-coded distance map	To analyze the reliability of a landmark-independent method for determining facialsymmetry
Hennessey (2006)	Laser scanning	No	24	Calculation of the asymmetry vector for each subject produced by subtracting the coordinates of the mirrored configuration of landmarks from the original configuration	To examine covariance of facial shape and asymmetry with cognition in a normal sample
Hood (2003)	Stereo-photogrammetry	No	Not defined	Calculation of an asymmetry index based on the mean distances between original and mirrored configurations of landmarks superimposed	To determine the degree of facial asymmetry in infants with unilateral cleft lip and/or palate, and 3D quantify improvements following primary surgery
Huang (2013)	Stereo-photogrammetry	Yes	16	Calculation of an asymmetry index	To differentiate a symmetric face from an asymmetric face by analyzing a three-dimensional facial image

(Table 2) contd.....

Study	Techniques Used	Use of Reference Planes	Number of Landmarks	Methods to Quantify the Asymmetry	Aim of the Study
Hwang (2006)	CBCT	Yes	21	Comparison between six "dimensions" (bilateral distances and bilateral angles)	To describe the use of 3D images in the diagnosis of facial asymmetry
Kamata (2017)	CBCT	Yes	14	Calculation of linear and angular measurements, comparison between subjects with and without facial asymmetry	To elucidate the factors that cause facial asymmetry by comparing the characteristics of the mandibular morphology in patients with mandibular prognathism with or without facial asymmetry
Katsumata (2005)	CBCT	Yes	22	Calculation of a linear asymmetry index	To test a 3D coordinate point evaluation system to assess and diagnose patient with facial asymmetry
Kornreich (2016)	Stereo-photogrammetry	Yes	10	Creation of a color-coded map and histogram (based on RMS*** calculated on the original and mirrored images superimposed) and comparison among linear distances	To compare of global versus landmark analyses of facial asymmetry using 3D photogrammetry
Kwon (2006)	CBCT	Yes	34	Comparison between bilateral distances and angles, left-right differences between the distances of each bilateral points to the reference planes	To evaluate the morphological characteristics of the cranial base and the maxillomandibular structures of facial asymmetry in adult patients
Kwon (2019)	CBCT	Yes	24	Comparison between bilateral linear and angular measurements	To investigate morphologic differences between the ipsilateral and contralateral types of facial asymmetry
Leung (2018)	CBCT	Yes	38	Performing of a 3D cephalometric analysis	To propose a new classification of mandibular asymmetry by anatomical regions
Maeda (2006)	CBCT	Yes	21	Calculation of an asymmetry index (according to Katsumata)	To characterize the symmetrical features of patients with facial deformities and to suggest a classification system for facial asymmetry based on 3D computed tomography evaluation
Meyer-Marcotty (2011)	3D Optical sensor	Yes	None	Determination of the symmetry plane and generation of facial asymmetry through virtual incremental alteration	To analyze the perception of various degrees of facial asymmetry
Moro (2009)	CBCT, PA cephalograms	Yes	3	Comparison between bilateral distances to the reference plane	To compare a computed tomographic three-dimensional analysis with a model analysis to use it as diagnostic aid for the evaluation of occlusal plane tilting in facial asymmetry
Nkenke (2006)	3D Optical sensor	Yes	26	Determination of the symmetry plane, comparison between bilateral distances, virtual volumes and angles	To assess measurement errors of a novel technique for the 3D determination of the degree of facial symmetry in patients suffering from unilateral cleft lip and palate malformations
Nur (2016)	CBCT	Yes	22	Comparison between bilateral linear, surface distance, angular, volumetric, and surface area measurements	To evaluate facial asymmetry three-dimensionally using CBCT and compare the right and left facial hard and soft tissues volumetrically and their interferences on each other

(Table 2) contd.....

Study	Techniques Used	Use of Reference Planes	Number of Landmarks	Methods to Quantify the Asymmetry	Aim of the Study
O'Grady (1999)	Laser scanning	Yes	26	Calculation of Euclidean distance matrix analysis (landmarks) and clearance vector (distance between superimposed surface), comparison between bilateral surface contour, surface areas, volumes	To evaluate six different techniques with respect to their ability to quantitatively describe facial asymmetry
Ostwald (2015)	3D Optical sensor	Yes	None	Calculation of an asymmetry index (average distance between original and reflected surface), creation of a color-coded map and histogram (based on the asymmetry index values), use of a visual analog scale to rate symmetry (subjective rating)	To answered different questions: is symmetry an appropriate value to describe facial variations? Is there a correlation between rated symmetry and attractiveness scores? Is there a correlation between (objective) (a)symmetry and rated (subjective) symmetry?
Ozsoy (2016)	Laser scanning (hand-held scanner)	Yes	11	Creation of a color-coded distance maps (based on calculation of RMS, MAD ¹ , MSD ² on the original and mirrored images superimposed)	To analyze the global and partial asymmetry of facial soft tissues using three different calculation methods and investigate the relationships among them
Park (2012)	CBCT	Yes	12	Comparison between the bilateral distances of the reference points from the reference planes	To characterize symmetrical features of patients with facial asymmetry and thus to find the most reliable horizontal reference lines easily used in 3D images
Patel (2015)	Stereo-photogrammetry	Yes	None	Creation of color-coded facial map and histogram starting from the superimposition between the original and mirrored images	To develop a technique to automatically localize and quantify soft-tissue asymmetry in adults using 3D facial scans
Pinheiro (2019)	CBCT	Yes	25	Performing of a3D cephalometric analysis	To evaluate a protocol for 3D cephalometric analysis for both the identification of the natural head position and the accurate quantification of facial growth and facial asymmetry is proposed and evaluated
Primožic (2012)	Laser scanning	Yes	2	Creation of a color-coded deviation map based on the average distances between mirrored images, determination of the predominance of either the left or right side of the face for each part of the face separately	To evaluate facial asymmetry in growing subjects with nomalocclusion on 3D laser facial scans
Ras (1995)	Stereo-photogrammetry	Yes	26	Calculation of the spatial distance of the minimal movement XY' to attain a symmetrical arrangement of the bilateral landmarks X and Y to the sagittal	To describe 3D developmental changes of facial asymmetry in children with an operated complete unilateral cleft lip and palate and in children without craniofacial anomalies
Sanders (2014)	CBCT	Yes	38	Comparison between bilateral distances	To identify and quantify the characteristics of facial and dental asymmetries in a normal, adolescent population using 3D images
Schwenzer-Zimmerer (2008)	Laser scanning	Yes	16	Creation of a color-coded distance map based on the scans superimposed, comparison between six pre and post treatment variables	To evaluate the clinical application of 3D imaging to analyze symmetry in cleft and non-cleft persons
Sforza (2007)	Contact digitalization	Yes	50	Calculation of a linear asymmetry index	To compare skeletal class III patients with normal subjects in the field of facial asymmetry

(Table 2) contd.....

Study	Techniques Used	Use of Reference Planes	Number of Landmarks	Methods to Quantify the Asymmetry	Aim of the Study
Shaner (2000)	Stereo-photogrammetry	Yes	28	Comparison between distances between two landmarks, angles between two landmarks and the horizontal plane, and depths; calculation of 3D coordinates of the landmarks and the coordinate direction angles of the landmarks	To determine if facial asymmetry was greater in syndrome-affected individuals than in normal individuals
Shin (2016)	CBCT	Yes	34	Calculation of the distances between the median cephalometric landmarks and the individual symmetric midsagittal reference plane	To determine, by statistical shape analysis of original and mirrored skeletal landmarks, the optimal landmark-based midsagittal reference plane for evaluation of facial asymmetry
Sievers (2012)	CBCT	Yes	22	Calculation of an asymmetry index (according to Katsumata)	To estimate possible differences in skeletal asymmetry between patients with skeletal Class I and skeletal Class II relationships
Stauber (2008)	3D Optical sensor	Yes	26	Comparison between bilateral distances, virtual volumes and angles (Nkenke's method)	To present a new technique to determine the plane of symmetry of a face, and to assess the degree of facial symmetry in patients with unilateral cleft lip
Taylor (2014)	Stereo-photogrammetry	No	None	Creation of a color-coded distance map (based on calculation of RMSD on original and reflected images superimposed)	To demonstrate a method for reproducibly and rapidly calculating a single number value for facial surface symmetry with a plane of maximum symmetry
Verhoeven (2013)	Stereo-photogrammetry	Yes	6	Creation of a color-coded distance map based on absolute mean distances between original and mirrored images superimposed	To introduce and validate a new method that quantifies soft-tissue facial asymmetry in patients who have undergone mandibular reconstruction
Verhoeven (2016)	Stereo-photogrammetry	Yes	19	Creation of a color-coded distance map based on the absolute mean distance between the original and mirrored images	To compare the validity and reproducibility of four different methods for the quantification of soft tissue facial asymmetry
Wermker (2014)	Stereo-photogrammetry	Yes	12	Calculation of an asymmetry index (mean of all distances between original and mirrored dataset superimposed) and created of a false-color map	To document and analyze the results of orthognathic surgery, to assess the soft tissue response related to the skeletal shift and the alterations in facial symmetry after orthognathic surgery
Wong (2014)	CBCT	Yes	4	Determination of the voxel-based optimal plane of symmetry	To introduce a new method of planning surgical correction of facial asymmetry using the OSPs as guides and test its effectiveness
Yanez-Vico (2011)	CBCT	Yes	14	Calculation of a linear asymmetry index, six Hwang's dimensions	To use 3D reconstructions of computed tomography to evaluate facial asymmetry
Yanez-Vico (2013)	CBCT	Yes	31	Comparison between bilateral distances and between normal and not normal subjects' cephalometric measurements (maxillary, mandibular and dento-alveolar)	To introduce a new three-dimensional analysis of clinical value for evaluating asymmetry in cases of craniofacial syndrome
Yang (2016)	CBCT	Yes	26	Calculation of an asymmetry index (linear)	To examine facial asymmetry in patients with unilateral cleft lip and palates

(Table 2) contd.....

Study	Techniques Used	Use of Reference Planes	Number of Landmarks	Methods to Quantify the Asymmetry	Aim of the Study
You (2018)	CBCT	Yes	25	Comparison between bilateral distances and angles	To analyze the morphologic features of skeletal units in the mandibles of patients with facial asymmetry and mandibular retrognathism

techniques. * RMSE = Root mean square error; ** RMSD = Root mean square distance; *** RMS = Root mean square; ¹ MAD = Mean absolute deviation; ² MSD = Mean square distance.

Laser scanner emanates an electromagnetic impulse (the “laser”) and receives the reflected signal, calculating time lapse passed and subsequently the distance between the instrument and the detected point. Data acquisition permit to obtain several points that define the object or subject surface and that are reworked in 3D models of the patient [34, 42].

3D optical sensors fall into the category of structured light techniques, such as stereophotogrammetry. They are based the triangulation principles, as well described by Kau [34] as follows. “Normally, a projector shines a pattern of ‘structured’ light (which may be composed of elliptical patterns, random texture maps, etc.) onto a targeted surface to be scanned. When the light illuminates the surface, the light pattern distorts and bends. A system of cameras at a known distance captures the reflected and distorted pattern under an angle and translates the information into 3D coordinates” [34].

Contact digitalization uses direct contact with the subject to obtain a 3D-dimensional reconstruction of the patient’s surface, based on single points. This means that the patient’s face becomes a framework and not a complete model where only landmarks are rebuilt, and not the complete surface of the face [43].

4. DISCUSSION

The observation of facial or dental asymmetry in patients, both mild or severe, is an important finding because symmetry and averageness are fundamental in order to increase facial aesthetics. There are different techniques to identify facial asymmetry to support clinical examination, mainly divided into 2D and 3D techniques.

4.1. Two-Dimensional Techniques

Two-dimensional techniques can be considered as first-level exams in the diagnosis of facial asymmetries. In particular, posterior-anterior cephalogram is the most commonly used radiograph to detect this kind of problem, despite it is characterised by limits and errors [22, 24]. For example, in Yanez-Vico’s systematic review on facial asymmetry (2010) [22] it is reported that a simple head rotation can modify the perpendicularity of cranial middle sagittal line in relation to the x-ray, leading to falsified calculations. Moreover, median sagittal line identification can be extremely difficult in patients affected by severe asymmetries. Trpkova [44] and Legrell [45] outline two recurrent errors in posterior-anterior cephalogram: those connected to cephalometric method (head rotation and object-film distance) and those inherent to the method itself (identification of landmarks and superimposition of anatomic structures). PA cephalogram remains a bidimensional representation of 3D structures and provides limited information about vertical and posterior-

anterior dimensions. However, facial asymmetry distorts cephalometric measurements both in 2D and 3D [37]. In addition to these limits, Mayor [46] outlines the need to use “reliable localization” landmarks (*i.e.* landmarks with intra and inter-examiner variation less than 1.5 mm) in order to reduce the second type of errors existing in posterior-anterior cephalogram. PA cephalogram exposes patients to a low dose of radiation as compared to its radiographic 3D counterparts. As regards the non-radiographic counterpart, digital photography completes clinical examination and makes it more accurate but, once again, it is a bidimensional representation of tridimensional structures. Both posterior-anterior cephalogram and digital photography are simple to learn and low-cost techniques.

In view of the above-mentioned advantages and disadvantages, the problem to quantify facial asymmetry through these techniques remains. According to Berlin’s systematic review [5] the most recommended methods are those that calculate facial asymmetry index. Nakamura [47], Baudouin [48] and Grammer [49] quantify asymmetry by means of a numerical parameter that allow the subsequent comparisons among patients. However, this unique measurement provides little or no information on the part of the face mainly being disharmonic. Clinicians may need to carry out analysis on a smaller scale to analyse small facial areas, to measure single angles and areas as well as to calculate more than one asymmetry index (possibly adding them in a total facial asymmetry index), in order to identify the components responsible for the facial disharmony. Yu [50] exposes ideal diagnostic methods requirements for facial asymmetry: it has to be simple to use without long training in landmarks identification, simple to understand and communicate to patients, cheap and characterized by minimal and essential number of measurements. According to Yu’s recommendations, Baudouin’s method [48] implicates an excessive number of landmarks (53), in contrast to Nakamura and Grammer’s ones [47, 49]. All three methods are cheap and used landmarks are simple to identify. Nakamura and Baudouin analyse both hard and soft tissues and provide a fuller vision, etiologically speaking, of the asymmetry. Several authors do not calculate any asymmetry index. Above all, they measure and compare bilateral distances, generally starting from the identification of reference points and lines [18, 34, 44, 51 - 57]. Therefore, their analysis focuses on the disharmony of the individual elements without calculating an asymmetry index that allows to quantify the facial imbalance in a simpler and a more immediate way. One author deviates from Yu’s recommendations as he identifies many landmarks [44]. On the contrary, most of them foresee from a minimum of 2 to a maximum of 14 reference points in their studies [55, 58].

Table 3. Methods and their characteristics to quantify the asymmetry by two-dimensional techniques.

Two-Dimensional Techniques to Diagnose Facial Asymmetry			
Types of Techniques	OPG	PA Cephalogram	Digital Photography
Advantages	Panoramic vision of teeth and jaws; low dose of radiation.	First level exam in the diagnosis of facial asymmetry; low dose of radiation.	Useful for soft-tissue asymmetry analysis
Disadvantages	Distortion; magnification; diagnosis limited to condyle and mandibular ramus asymmetries; 2D vision of 3D structures.	Distortion; magnification; superimposition of anatomical structures; 2D vision of 3D structures.	2D vision of 3D structures
Methods to quantify the asymmetry	Calculation of an asymmetry index; comparison between bilateral distances.	Calculation of an asymmetry index; comparison between bilateral distances and areas; performing of a cephalometric analysis; evaluation of the coincidence between two lines.	Calculation of an asymmetry index; comparison between bilateral distance, angles and areas; calculation of EDMA*; ratings of similarity between mirrored faces

*Euclidean Distance Matrix Analysis (EDMA) is a landmark-based method that uses landmark coordinate data to calculate all possible linear distances among landmarks, creating a form matrix for each object.

Table 4. Methods and their characteristics to quantify the asymmetry by three-dimensional techniques.

Three-Dimensional Techniques to Diagnose Facial Asymmetry					
Types of Techniques	CB-CT	Stereophotogrammetry	Laser Scanning	3D Optical Sensors (Computer-Aided Structured Light)	Contact Digitalization
Advantages	3D vision of structures; lack of superimposition; measurements accuracy.	Realistic and accurate rendering of the face surface easy to set up.	High resolution; medium photorealistic quality; acquisition of contour, topology and surface data; existence of low-cost scanner.	Photorealistic rendering of the face surface; very rapid capture.	Non-invasive.
Disadvantages	More expensive and higher dose of radiation than 2D radiographic methods; artefacts.	Initial training; suitable and expensive equipment; inaccurate rendering of some parts (like hairs); magnification errors; tedious work to map surfaces.	Remarkable duration (need of patient stillness); initial training; suitable equipment.	Variable resolution quality; sensitive to the technique.	Initial training; remarkable duration; suitable equipment; face recreation through points that outline the surface.
Methods to quantify asymmetry	Calculation of an asymmetry index; comparison between bilateral distances, angles and volumes; creation of a color-coded distance map; determination of the plane of symmetry; performing of a 3D cephalometric analysis.	Creation of a color-coded distance map; calculation of an asymmetry index; comparison between bilateral distances; comparison between the patient's original configuration and the symmetrical one.	Creation of a color-coded distance map; comparison between bilateral distances, angles, areas, volumes and contours; calculation of an asymmetry index or an asymmetry vector.	Determination of the plane of symmetry; comparison between bilateral distances, angles and volumes; creation of a color-coded distance map; calculation of an asymmetry index.	Calculation of an asymmetry index; comparison between bilateral distances and angles

About landmarks and reference lines, most authors use points validated by the literature, such as the ones easier to identify and the ones their localization is subjected to fewer errors, following in particular Farkas' studies [59, 60]. The methods used are relatively simple to communicate and share with patients, in particular, if based on a limited number of reference points and measurements, such as those stated in the findings of Edler [61], Danel [55], Eskelsen [62], Saglam [63]. The two-dimensional techniques are cheaper than the three-dimensional ones both with reference to the execution costs of a photograph, an OPG or a PA cephalogram and with reference to the software necessary to carry out the analysis of the facial asymmetry.

Dealing with the validation of the methods in term of accuracy, reliability and reproducibility, there is limited data. Repeatability levels in the identification of landmarks and reference lines, in the execution of the measurements and in the methods themselves, both in cephalometric and photographic tracings, appear satisfactory overall [44, 53, 56, 61, 64 - 66]. In terms of accuracy and reproducibility, Berlin [5] underlines in her review that “an adequate number of evenly distributed and reproducible reference points should be used, which cover all areas significant for symmetry” (she proposes 25 landmarks). “Several independent examiners should determine the reference points in order to reduce the uncertainty of subjective identification”. Using a large number of points increase both the accuracy and the expenses and using one or more reference

lines can equally cause a problem if they are defined from two landmarks that are not positioned correctly. According to these considerations, the methods of Nakamura [47], Ercan [65], Baudouin [48], Trpkova [44] seem to be the most accurate as they calculate the highest number of reference points. However, they are characterized by the use of reference lines, with their associated advantages and disadvantages. In Ercan's study [65], the same investigator makes 42 landmarks twice, one month apart, and calculates the intrarater reliability coefficient for a two-facet crossed design ('landmark pairs-by-rater-by-subject'). In Trpkova's paper [44] the investigator error is evaluated by three repeated digitizations.

The following table summarizes advantages, disadvantages and methods to quantify the asymmetry related to two-dimensional techniques (Table 3).

4.2. Three-Dimensional Techniques

Three-dimensional techniques provide more accurate and detailed information for the diagnosis and treatment planning of facial asymmetry. The disadvantages and limits that are typical of two-dimensional techniques, such as distortion, magnification and superimposition of anatomical structures are strictly reduced. However, the problem of the patient's positioning during the examination, the need for no movements while the exam is performed (especially if clinicians use laser scanning and contact digitalization techniques) and the distortion of cephalometric measurements caused by facial asymmetry remain [67, 68].

CBCT represents the principal three-dimensional radiographic technique. It allows the exact determination and visualization of the patient's hard and soft tissues. It makes it possible to visualize axial, sagittal and coronal sections of the acquired volume in order to obtain aorthopantom-like and cephalogram-like images and, through a three-dimensional rendering process, to make a three-dimensional reconstruction of the studied volume. It is significant for the identification of craniofacial disproportions and it can also be used to evaluate any causes of craniofacial asymmetries during growth, which may also arise from developmental abnormalities involving the craniofacial sutures and craniofacial modifications due to exogenous forces such as orthodontic ones [69 - 75]. On the other hand, CBCT exposes patients to a higher dose of radiation and it is more expensive than its two-dimensional counterparts. All authors included in this review use reference points and planes. Although the same problems exist regarding the choice of reference planes and reference points of the two-dimensional quantification of facial asymmetry, there are advantages thanks to a more accurate reconstruction of the anatomical structures and the possibility of using cranial base points as landmarks. Five authors calculate a linear asymmetry index based on the differences between bilateral distances in the three dimensions [76 - 80]. In particular, Katsumata [76] obtains an asymmetry index for any points that can be symmetrical, asymmetrical or marked asymmetrical. The number of landmarks used in these studies varies from 14 to 26 and the reference planes from 3 to 6, with a good balance between Yu's recommendation [50] regarding a minimum and essential number of points and measures and the need to obtain

accurate measurements. Twelve authors compare bilateral distances, angles, areas and volumes for analysing facial asymmetry [12, 81 - 91]. Probably the easiest method used is the Hwang's one [81], which calculates six "dimensions" (starting from 12 points and 3 planes) that allow the description of the facial asymmetry comparing left and right maxillary and mandibular linear measurements and angles. Through these methods, it is possible to identify structures and "areas" mainly involved in patients' disharmony (maxillary height, mandibular body height and length, frontal and lateral angulation of mandibular branch, mandibular branch height). It seems to be a simple method to use and to communicate to the patients. The methods of Economou and Sanders [86, 89], on the other hand, implicate the largest numbers of landmarks (38) and, consequently, the largest number of bilateral measurements. Two authors [83, 92] consider CBCT a typical modality of analysis for soft tissue disharmony: the creation of a color-coded distance map, by far the most used method to delineate the asymmetry through stereophotogrammetry [93 - 103]. This type of map is generated as follows. First of all, the original image of the patient's face, digitally reconstructed, is reflected around a plane that can be arbitrary external to the face itself or internal, sagittal and median. Then the two images, the original and the reflected ones, are superimposed, generally minimizing their distance through special algorithms such as ICP (Iterative Closest Point). Different colours present, in an immediate and easily understandable way, the residual distances (which represent the degrees of asymmetry) between the numerous points make up the digital images. The remaining distances can be calculated as RMSE (Root Mean Square Error), MAD (Mean Absolute Deviation) or MSD (Mean Square Distances). Eleven authors create a color-coded distance map using stereophotogrammetry [93 - 103], seven authors using laser scanning [42, 104 - 109], and two authors using 3D optical sensors [110, 111]. This type of method requires an adequate software (generally quite expensive) to superimpose images and to measure their distances but does not require the identification of any landmarks. Two comparative studies about a landmark-based and a global or surface-based method (a method that implies the superimposition between the original image and the reflected one) have been performed by Verhoeven and Kornreich, evaluating the accuracy and the reproducibility of the methods themselves [99, 100]. Both authors claim that the "global approach" is more valid and reproducible than the landmark-based one. Moreover, intra and inter-observer performances are carefully tested by Verhoeven [93] in another paper with good results, confirmed by Kornreich [100]. The systematic error of the surface-based approach has been equally tested as well as the quality of scans or stereophotogrammetric images has been assessed [93, 95, 99, 100, 104, 105]. Given these premises, the so-called global approach, with the creation of a color-coded-distance map, seems to be the most accurate, reproducible and validated method in the literature for the quantification of soft tissue asymmetry.

There is no shortage of authors who calculate an asymmetry index or compare bilateral distances, angles and volumes [42, 89, 97, 102, 105, 106, 112 - 121] using stereophotogrammetry, laser scanning and 3D optical sensors.

Some authors combine multiple methods. For example, Ostwald [111] calculates an asymmetry index and starting from those values, he creates a color-coded map [122]. His index allows him to easily compare the pre- and post-surgical asymmetry of the patients involved in his study. The contact digitalization techniques are rarely used (addressed in only two selected studies) [43, 123]. In particular, Sforza [43] calculates 17 unilateral and bilateral landmarks, 19 unilateral and bilateral distances between landmarks, the “individual symmetry midline” for each patient and two “gravity centres” of each side of his/her face. The deviation of landmarks from symmetry midline provides “facial midline asymmetry index”, the distance between “gravity centres” supplies “facial lateral asymmetry index” and the total of them produces “total asymmetry index”. This method is accurate and it allows a detailed analysis of the patient’s disharmony but it requires remarkable numbers of points, measurements and calculations. It also requires the patient to stay still for the time needed to complete the examination, which is not insignificant. Finally, it is necessary to remember that stereophotogrammetry, laser scanning, 3D optical sensor and contact digitalization require an adequate equipment and an initial training for their correct use [124].

The following table summarizes advantages, disadvantages and methods to quantify the asymmetry related to three-dimensional techniques (Table 4).

CONCLUSION

Clinical examination represents the first fundamental step in the diagnosis of facial asymmetry. It shows the presence of sagittal, coronal and vertical asymmetry and it is divided into an extra-oral and an intra-oral examination. Amongst 2D techniques, PA cephalogram represents the first level exam to quantify facial asymmetry, whilst an OPG can only be used to diagnose mandibular and/or condylar asymmetry. Digital photography completes the clinical evaluation and makes it more accurate. The most reliable methods to quantify facial asymmetry are those that calculate an asymmetry index based on an adequate (but not excessive) number of correctly located points, with or without the identification of reference lines. 3D techniques represent the second level examination in the diagnosis of facial asymmetry. The most used techniques are CBCT, stereophotogrammetry, laser scanning, 3D optical sensors and contact digitization. Comparing bilateral parameters (linear distances, angles, areas, volumes and contours) and calculating an asymmetry index seems to be the best choice for clinicians who use CBCT. The creation of a color-coded distance map, which is a surface-based method that requires no reference points, seems to represent the most accurate, reliable and validated method for clinicians who use stereophotogrammetry, laser scanning and 3D optical sensors.

CONSENT FOR PUBLICATION

Not applicable.

STANDARDS OF REPORTING

PRISMA guidelines and methodologies were followed in this study.

FUNDING

None.

CONFLICT OF INTEREST

The authors declare no conflict of interest, financial or otherwise.

ACKNOWLEDGEMENTS

Declared none.

SUPPLEMENTARY MATERIAL

PRISMA checklist is available as supplementary material on the publisher’s website along with the published article.

REFERENCES

- [1] Enquist M, Arak A. Symmetry, beauty and evolution. *Nature* 1994; 372(6502): 169-72. [http://dx.doi.org/10.1038/372169a0] [PMID: 7969448]
- [2] Springer IN, Wannicke B, Warnke PH, *et al.* Facial attractiveness: visual impact of symmetry increases significantly towards the midline. *Ann Plast Surg* 2007; 59(2): 156-62. [http://dx.doi.org/10.1097/01.sap.0000252041.66540.ec] [PMID: 17667409]
- [3] Hönn M, Göz G. The ideal of facial beauty: A review. *J Orofac Orthop* 2007; 68(1): 6-16. [http://dx.doi.org/10.1007/s00056-007-0604-6] [PMID: 17238049]
- [4] Borelli C, Berneburg M. “Beauty lies in the eye of the beholder”? Aspects of beauty and attractiveness. *J Dtsch Dermatol Ges* 2010; 8(5): 326-30. [http://dx.doi.org/10.1111/j.1610-0387.2009.07318_supp.x] [PMID: 20537001]
- [5] Berlin NF, Berssenbrügge P, Runte C, *et al.* Quantification of facial asymmetry by 2D analysis - A comparison of recent approaches. *J Craniomaxillofac Surg* 2014; 42(3): 265-71. [http://dx.doi.org/10.1016/j.jcms.2013.07.033] [PMID: 24041610]
- [6] Bishara SE, Burkey PS, Kharouf JG. Dental and facial asymmetries: A review. *Angle Orthod* 1994; 64(2): 89-98. [PMID: 8010527]
- [7] Hinds EC, Reid LC, Burch RJ. Classification and management of mandibular asymmetry. *Am J Surg* 1960; 100: 825-34. [http://dx.doi.org/10.1016/0002-9610(60)90513-4] [PMID: 13714432]
- [8] Beyer JW, Lindauer SJ. Evaluation of dental midline position. *Semin Orthod* 1998; 4(3): 146-52. [http://dx.doi.org/10.1016/S1073-8746(98)80016-9] [PMID: 9807151]
- [9] Peck S, Peck L, Kataja M. Skeletal asymmetry in esthetically pleasing faces. *Angle Orthod* 1991; 61(1): 43-8. [PMID: 2012321]
- [10] Cheong YW, Lo L.J. Facial asymmetry: Etiology, evaluation, and management. *Chang Gung Med J* 2011; 34(4): 341-51. [PMID: 21880188]
- [11] Thiesen G, Gribel BF, Freitas MP. Facial asymmetry: A current review. *Dental Press J Orthod* 2015; 20(6): 110-25. [http://dx.doi.org/10.1590/2177-6709.20.6.110-125.sar] [PMID: 26691977]
- [12] Kwon TG, Park HS, Ryoo HM, Lee SH. A comparison of craniofacial morphology in patients with and without facial asymmetry--A three-dimensional analysis with computed tomography. *Int J Oral Maxillofac Surg* 2006; 35(1): 43-8. [http://dx.doi.org/10.1016/j.ijom.2005.04.006] [PMID: 15925488]
- [13] Severt TR, Proffit WR. The prevalence of facial asymmetry in the dentofacial deformities population at the University of North Carolina. *Int J Adult Orthodon Orthognath Surg* 1997; 12(3): 171-6. [PMID: 9511487]
- [14] Sheats RD, McGorray SP, Musmar Q, Wheeler TT, King GJ. Prevalence of orthodontic asymmetries. *Semin Orthod* 1998; 4(3): 138-45. [http://dx.doi.org/10.1016/S1073-8746(98)80015-7] [PMID: 9807150]
- [15] Bailey LJ, Haltiwanger LH, Blakey GH, Proffit WR. Who seeks surgical-orthodontic treatment: A current review. *Int J Adult Orthodon Orthognath Surg* 2001; 16(4): 280-92.

- [PMID: 12390006]
- [16] Willems G, De Bruyne I, Verdonck A, Fieuws S, Carels C. Prevalence of dentofacial characteristics in a Belgian orthodontic population. *Clin Oral Invest* 2001; 5(4): 220-6. [http://dx.doi.org/10.1007/s007840100128] [PMID: 11800434]
- [17] Samman N, Tong AC, Cheung DL, Tideman H. Analysis of 300 dentofacial deformities in Hong Kong. *Int J Adult Orthodon Orthognath Surg* 1992; 7(3): 181-5. [PMID: 1291612]
- [18] Haraguchi S, Takada K, Yasuda Y. Facial asymmetry in subjects with skeletal Class III deformity. *Angle Orthod* 2002; 72(1): 28-35. [PMID: 11843270]
- [19] Ramirez-Yañez GO, Stewart A, Franken E, Campos K. Prevalence of mandibular asymmetries in growing patients. *Eur J Orthod* 2011; 33(3): 236-42. [http://dx.doi.org/10.1093/ejo/cjq057] [PMID: 20724557]
- [20] Lindauer SJ. Asymmetries: Diagnosis and treatment. *Semin Orthod* 1998; 4(3): 133. [http://dx.doi.org/10.1016/S1073-8746(98)80013-3] [PMID: 9807148]
- [21] Burstone CJ. Diagnosis and treatment planning of patients with asymmetries. *Semin Orthod* 1998; 4(3): 153-64. [http://dx.doi.org/10.1016/S1073-8746(98)80017-0] [PMID: 9807152]
- [22] Yañez-Vico RM, Iglesias-Linares A, Torres-Lagares D, Gutiérrez-Pérez JL, Solano-Reina E. Diagnostic of craniofacial asymmetry. Literature review. *Med Oral Patol Oral Cir Bucal* 2010; 15(3): e494-8. [http://dx.doi.org/10.4317/medoral.15.e494] [PMID: 20038905]
- [23] Santariello C, Ballanti F, Baroni M, Baldini A, Bollero P, Cozza P. Diagnostic and clinical evaluation of skeletal asymmetries of orthodontic interest. *Dent Cadmos* 2015; 83(1): 9-14. [http://dx.doi.org/10.1016/S0011-8524(15)70257-6]
- [24] Srivastava D, Singh H, Mishra S, Sharma P, Kapoor P, Chandra L. Facial asymmetry revisited: Part I- diagnosis and treatment planning. *J Oral Biol Craniofac Res* 2018; 8(1): 7-14. [http://dx.doi.org/10.1016/j.jobcr.2017.04.010] [PMID: 29556456]
- [25] Akhil G, Senthil Kumar KP, Raja S, Janardhanan K. Three-dimensional assessment of facial asymmetry: A systematic review. *J Pharm Bioallied Sci* 2015; 7(Suppl. 2): S433-7. [http://dx.doi.org/10.4103/0975-7406.163491] [PMID: 26538893]
- [26] Chia MS, Naini FB, Gill DS. The aetiology, diagnosis and management of mandibular asymmetry 2008. Available from: <https://www.mysurgerywebsite.co.uk/website/IGP580/files/asymmetries.pdf> [http://dx.doi.org/10.12968/ortu.2008.1.2.44]
- [27] Bricchi E. Diagnosi 2D vs diagnosi 3D: La conebeam computed tomography in ortognatodonzia. *Dent Moderno* 2015; 4: 28-43.
- [28] Van Elslande DC, Russett SJ, Major PW, Flores-Mir C. Mandibular asymmetry diagnosis with panoramic imaging. *Am J Orthod Dentofacial Orthop* 2008; 134(2): 183-92. [http://dx.doi.org/10.1016/j.ajodo.2007.07.021] [PMID: 18675198]
- [29] Yamashita Y, Nakamura Y, Shimada T, Nomura Y, Hirashita A. Asymmetry of the lips of orthognathic surgery patients. *Am J Orthod Dentofacial Orthop* 2009; 136(4): 559-63. [http://dx.doi.org/10.1016/j.ajodo.2007.10.057] [PMID: 19815159]
- [30] Scheib JE, Gangestad SW, Thornhill R. Facial attractiveness, symmetry and cues of good genes. *Proc Biol Sci* 1999; 266(1431): 1913-7. [http://dx.doi.org/10.1098/rspb.1999.0866] [PMID: 10535106]
- [31] Shin SM, Kim YM, Kim NR, Choi YS, Park SB, Kim YI. Statistical shape analysis-based determination of optimal midsagittal reference plane for evaluation of facial asymmetry. *Am J Orthod Dentofacial Orthop* 2016; 150(2): 252-60. [http://dx.doi.org/10.1016/j.ajodo.2016.01.017] [PMID: 27476357]
- [32] An S, Lee JY, Chung CJ, Kim KH. Comparison of different midsagittal plane configurations for evaluating craniofacial asymmetry by expert preference. *Am J Orthod Dentofacial Orthop* 2017; 152(6): 788-97. [http://dx.doi.org/10.1016/j.ajodo.2017.04.024] [PMID: 29173858]
- [33] Wong TY, Liu JK, Fang JJ, Wu TC, Tu YH. Use of the matching optimal symmetry plane method in planning surgical correction of facial asymmetry--A preliminary report of 20 patients. *J Oral Maxillofac Surg* 2014; 72(6): 1180.e1-1180.e13. [http://dx.doi.org/10.1016/j.joms.2014.02.020] [PMID: 24742699]
- [34] Kau CH, Richmond S, Incrapera A, English J, Xia JJ. Three-dimensional surface acquisition systems for the study of facial morphology and their application to maxillofacial surgery. *Int J Med Robot* 2007; 3(2): 97-110. [http://dx.doi.org/10.1002/rcs.141] [PMID: 17619242]
- [35] Benz M, Laboureux X, Maier T, *et al.* The symmetry of faces. Vision, modelling, and visualization. Amsterdam, The Netherlands: IOS Press 2002; pp. 332-9.
- [36] Meyer-Marcotty P, Stellzig-Eisenhauer A, Bareis U, Hartmann J, Kochel J. Three-dimensional perception of facial asymmetry. *Eur J Orthod* 2011; 33(6): 647-53. [http://dx.doi.org/10.1093/ejo/cjq146] [PMID: 21355063]
- [37] Gateno J, Xia JJ, Teichgraber JF. Effect of facial asymmetry on 2-dimensional and 3-dimensional cephalometric measurements. *J Oral Maxillofac Surg* 2011; 69(3): 655-62. [http://dx.doi.org/10.1016/j.joms.2010.10.046] [PMID: 21353927]
- [38] Hajeer MY, Ayoub AF, Millett DT. Three-dimensional assessment of facial soft-tissue asymmetry before and after orthognathic surgery. *Br J Oral Maxillofac Surg* 2004; 42(5): 396-404. [http://dx.doi.org/10.1016/j.bjoms.2004.05.006] [PMID: 15336764]
- [39] Bugaighis I, Mattick CR, Tiddeman B, Hobson R. 3D asymmetry of operated children with oral clefts. *Orthod Craniofac Res* 2014; 17(1): 27-37. [http://dx.doi.org/10.1111/ocr.12026] [PMID: 23848596]
- [40] Ras F, Habets LL, van Ginkel FC, Prah-Andersen B. Longitudinal study on three-dimensional changes of facial asymmetry in children between 4 to 12 years of age with unilateral cleft lip and palate. *Cleft Palate Craniofac J* 1995; 32(6): 463-8. [http://dx.doi.org/10.1597/1545-1569_1995_032_0463_lsotdc_2.3.co_2] [PMID: 8547285]
- [41] Heike CL, Upton K, Stuhau E, Weinberg SM. 3D digital stereophotogrammetry: A practical guide to facial image acquisition. *Head Face Med* 2010; 6: 18. [http://dx.doi.org/10.1186/1746-160X-6-18] [PMID: 20667081]
- [42] Schwenzer-Zimmerer K, Chaitidis D, Berg-Boerner I, *et al.* Quantitative 3D soft tissue analysis of symmetry prior to and after unilateral cleft lip repair compared with non-cleft persons (performed in Cambodia). *J Craniomaxillofac Surg* 2008; 36(8): 431-8. [http://dx.doi.org/10.1016/j.jcms.2008.05.003] [PMID: 18701312]
- [43] Sforza C, Peretta R, Grandi G, Ferronato G, Ferrario VF. Three-dimensional facial morphometry in skeletal Class III patients. A non-invasive study of soft-tissue changes before and after orthognathic surgery. *Br J Oral Maxillofac Surg* 2007; 45(2): 138-44. [http://dx.doi.org/10.1016/j.bjoms.2005.12.013] [PMID: 16483700]
- [44] Trpkova B, Prasad NG, Lam EW, Raboud D, Glover KE, Major PW. Assessment of facial asymmetries from posteroanterior cephalograms: Validity of reference lines. *Am J Orthod Dentofacial Orthop* 2003; 123(5): 512-20. [http://dx.doi.org/10.1016/S0889-5406(02)57034-7] [PMID: 12750669]
- [45] Legrell PE, Nyquist H, Isberg A. Validity of identification of gonion and antegonion in frontal cephalograms. *Angle Orthod* 2000; 70(2): 157-64. [PMID: 10833005]
- [46] Major PW, Johnson DE, Hesse KL, Glover KE. Landmark identification error in posterior anterior cephalometrics. *Angle Orthod* 1994; 64(6): 447-54. [PMID: 7864466]
- [47] Nakamura T, Okamoto K, Maruyama T. Facial asymmetry in patients with cervicobrachial pain and headache. *J Oral Rehabil* 2001; 28(11): 1009-14. [http://dx.doi.org/10.1046/j.1365-2842.2001.00766.x] [PMID: 11722716]
- [48] Baudouin JY, Tiberghien G. Symmetry, averageness, and feature size in the facial attractiveness of women. *Acta Psychol (Amst)* 2004; 117(3): 313-32. [http://dx.doi.org/10.1016/j.actpsy.2004.07.002] [PMID: 15500809]
- [49] Grammer K, Thornhill R. Human (*Homo sapiens*) facial attractiveness and sexual selection: The role of symmetry and averageness. *J Comp Psychol* 1994; 108(3): 233-42. [http://dx.doi.org/10.1037/0735-7036.108.3.233] [PMID: 7924253]
- [50] Yu CC, Bergeron L, Lin CH, Chu YM, Chen YR. Single-splint technique in orthognathic surgery: Intraoperative checkpoints to control facial symmetry. *Plast Reconstr Surg* 2009; 124(3): 879-86. [http://dx.doi.org/10.1097/PRS.0b013e3181b03842] [PMID: 19730307]
- [51] Altug-Atac AT, Grayson BH, McCarthy JG. Comparison of skeletal and soft-tissue changes following unilateral mandibular distraction osteogenesis. *Plast Reconstr Surg* 2008; 121(5): 1751-9. [http://dx.doi.org/10.1097/PRS.0b013e31816aa003] [PMID: 18454000]

- [52] Hwang HS, Youn IS, Lee KH, Lim HJ. Classification of facial asymmetry by cluster analysis. *Am J Orthod Dentofacial Orthop* 2007; 132(3): 279.e1-6. [http://dx.doi.org/10.1016/j.ajodo.2007.01.017] [PMID: 17826592]
- [53] Good S, Edler R, Wertheim D, Greenhill D. A computerized photographic assessment of the relationship between skeletal discrepancy and mandibular outline asymmetry. *Eur J Orthod* 2006; 28(2): 97-102. [http://dx.doi.org/10.1093/ejo/cji097] [PMID: 16431897]
- [54] Penton-Voak IS, Jones BC, Little AC, *et al.* Symmetry, sexual dimorphism in facial proportions and male facial attractiveness. *Proc Biol Sci* 2001; 268(1476): 1617-23. [http://dx.doi.org/10.1098/rspb.2001.1703] [PMID: 11487409]
- [55] Danel D, Pawlowski B. Eye-mouth-eye angle as a good indicator of face masculinization, asymmetry, and attractiveness (*Homo sapiens*). *J Comp Psychol* 2007; 121(2): 221-5. [http://dx.doi.org/10.1037/0735-7036.121.2.221] [PMID: 17516801]
- [56] Gosla-Reddy S, Nagy K, Mommaerts MY, *et al.* Primary septoplasty in the repair of unilateral complete cleft lip and palate. *Plast Reconstr Surg* 2011; 127(2): 761-7. [http://dx.doi.org/10.1097/PRS.0b013e318200a97a] [PMID: 20966813]
- [57] Kjellberg H, Ekestubbe A, Kiliaridis S, Thilander B. Condylar height on panoramic radiographs. A methodologic study with a clinical application. *Acta Odontol Scand* 1994; 52(1): 43-50. [http://dx.doi.org/10.3109/00016359409096375] [PMID: 8184679]
- [58] Fong JH, Wu HT, Huang MC, *et al.* Analysis of facial skeletal characteristics in patients with chin deviation. *J Chin Med Assoc* 2010; 73(1): 29-34. [http://dx.doi.org/10.1016/S1726-4901(10)70018-6] [PMID: 20103488]
- [59] Farkas LG. Anthropometry of the head and face in medicine. New York: Elsevier North Holland Inc 1981.
- [60] Farkas LG, Munro IR. Anthropometric facial proportions in medicine. Springfield: Charles C Thomas 1987.
- [61] Edler R, Wertheim D, Greenhill D. Comparison of radiographic and photographic measurement of mandibular asymmetry. *Am J Orthod Dentofacial Orthop* 2003; 123(2): 167-74. [http://dx.doi.org/10.1067/mod.2003.16] [PMID: 12594423]
- [62] Eskelsen E, Fernandes CB, Pelogia F, *et al.* Concurrence between the maxillary midline and bisector to the interpupillary line. *J Esthet Restor Dent* 2009; 21(1): 37-41. [http://dx.doi.org/10.1111/j.1708-8240.2008.00229.x] [PMID: 19207457]
- [63] Saglam AA, Sanli G. Condylar asymmetry measurements in patients with temporomandibular disorders. *J Contemp Dent Pract* 2004; 5(3): 59-65. [http://dx.doi.org/10.5005/jcdp-5-3-59] [PMID: 15318257]
- [64] Edler R, Wertheim D, Greenhill D. Clinical and computerized assessment of mandibular asymmetry. *Eur J Orthod* 2001; 23(5): 485-94. [http://dx.doi.org/10.1093/ejo/23.5.485] [PMID: 11668868]
- [65] Ercan I, Ozdemir ST, Etoz A, *et al.* Facial asymmetry in young healthy subjects evaluated by statistical shape analysis. *J Anat* 2008; 213(6): 663-9. [http://dx.doi.org/10.1111/j.1469-7580.2008.01002.x] [PMID: 19094182]
- [66] Rikowski A, Grammer K. Human body odour, symmetry and attractiveness. *Proc Biol Sci* 1999; 266(1422): 869-74. [http://dx.doi.org/10.1098/rspb.1999.0717] [PMID: 10380676]
- [67] Leung MY, Leung YY. Three-dimensional evaluation of mandibular asymmetry: A new classification and three-dimensional cephalometric analysis. *Int J Oral Maxillofac Implants* 2018; 47(8): 1043-51. [http://dx.doi.org/10.1016/j.ijom.2018.03.021] [PMID: 29636307]
- [68] Pinheiro M, Ma X, Fagan MJ, *et al.* A 3D cephalometric protocol for the accurate quantification of the craniofacial symmetry and facial growth. *J Biol Eng* 2019; 13: 42. [http://dx.doi.org/10.1186/s13036-019-0171-6] [PMID: 31131023]
- [69] Savoldi F, Massetti F, Tsoi JKH, *et al.* Anteroposterior length of the maxillary complex and its relationship with the anterior cranial base. *Angle Orthod* 2021; 91(1): 88-97. [http://dx.doi.org/10.2319/020520-82.1] [PMID: 33289836]
- [70] Laffranchi L, Dalessandri D, Tonni I, Paganelli C. Use of CBCT in the orthodontic diagnosis of a patient with pycnodysostosis. *Minerva Stomatol* 2010; 59(11-12): 653-61. [PMID: 21217630]
- [71] Dalessandri D, Laffranchi L, Tonni I, *et al.* Advantages of cone beam computed tomography (CBCT) in the orthodontic treatment planning of cleidocranial dysplasia patients: A case report. *Head Face Med* 2011; 7: 6. [http://dx.doi.org/10.1186/1746-160X-7-6] [PMID: 21352577]
- [72] Savoldi F, Tsoi JKH, Paganelli C, Matinlinna JP. Sutural morphology in the craniofacial skeleton: A descriptive microcomputed tomography study in a swine model. *Anat Rec (Hoboken)* 2019; 302(12): 2156-63. [http://dx.doi.org/10.1002/ar.24230] [PMID: 31433566]
- [73] Savoldi F, Tsoi JKH, Paganelli C, Matinlinna JP. The biomechanical properties of human craniofacial sutures and relevant variables in sutural distraction osteogenesis: A critical review. *Tissue Eng Part B Rev* 2018; 24(1): 25-36. [http://dx.doi.org/10.1089/ten.teb.2017.0116] [PMID: 28610544]
- [74] Savoldi F, Xu B, Tsoi JKH, Paganelli C, Matinlinna JP. Anatomical and mechanical properties of swine midpalatal suture in the premaxillary, maxillary, and palatine region. *Sci Rep* 2018; 8(1): 7073. [http://dx.doi.org/10.1038/s41598-018-25402-y] [PMID: 29728631]
- [75] Oliva G, Zotti R, Zotti F, *et al.* Integration of Cranial Base and Face in Growing Subject. *Appl Sci (Basel)* 2020; 10(7): 2508. Available from: https://www.mdpi.com/2076-3417/10/7/2508?type=check_update&version=2 [http://dx.doi.org/10.3390/app10072508]
- [76] Katsumata A, Fujishita M, Maeda M, Arijii Y, Arijii E, Langlais RP. 3D-CT evaluation of facial asymmetry. *Oral Surg Oral Med Oral Pathol Oral Radiol Endod* 2005; 99(2): 212-20. [http://dx.doi.org/10.1016/j.tripleo.2004.06.072] [PMID: 15660095]
- [77] Maeda M, Katsumata A, Arijii Y, *et al.* 3D-CT evaluation of facial asymmetry in patients with maxillofacial deformities. *Oral Surg Oral Med Oral Pathol Oral Radiol Endod* 2006; 102(3): 382-90. [http://dx.doi.org/10.1016/j.tripleo.2005.10.057] [PMID: 16920547]
- [78] Yáñez-Vico RM, Iglesias-Linares A, Torres-Lagares D, Gutiérrez-Pérez JL, Solano-Reina E. Three-dimensional evaluation of craniofacial asymmetry: An analysis using computed tomography. *Clin Oral Investig* 2011; 15(5): 729-36. [http://dx.doi.org/10.1007/s00784-010-0441-7] [PMID: 20632049]
- [79] Sievers MM, Larson BE, Gaillard PR, Wey A. Asymmetry assessment using cone beam CT. A Class I and Class II patient comparison. *Angle Orthod* 2012; 82(3): 410-7. [http://dx.doi.org/10.2319/041711-271.1] [PMID: 21978416]
- [80] Yang L, Chen Z, Zhang X. A cone-beam computed tomography evaluation of facial asymmetry in unilateral cleft lip and palate individuals. *J Oral Sci* 2016; 58(1): 109-15. [http://dx.doi.org/10.2334/josnusd.58.109] [PMID: 27021547]
- [81] Hwang HS, Hwang CH, Lee KH, Kang BC. Maxillofacial 3-dimensional image analysis for the diagnosis of facial asymmetry. *Am J Orthod Dentofacial Orthop* 2006; 130(6): 779-85. [http://dx.doi.org/10.1016/j.ajodo.2005.02.021] [PMID: 17169741]
- [82] Moro A, Correrá P, Boniello R, Gasparini G, Pelo S. Three-dimensional analysis in facial asymmetry: Comparison with model analysis and conventional two-dimensional analysis. *J Craniofac Surg* 2009; 20(2): 417-22. [http://dx.doi.org/10.1097/SCS.0b013e31819b96a5] [PMID: 19258903]
- [83] Damstra J, Oosterkamp BC, Jansma J, Ren Y. Combined 3-dimensional and mirror-image analysis for the diagnosis of asymmetry. *Am J Orthod Dentofacial Orthop* 2011; 140(6): 886-94. [http://dx.doi.org/10.1016/j.ajodo.2010.03.032] [PMID: 22133955]
- [84] Park JU, Kook YA, Kim Y. Assessment of asymmetry in a normal occlusion sample and asymmetric patients with three-dimensional cone beam computed tomography: A study for a transverse reference plane. *Angle Orthod* 2012; 82(5): 860-7. [http://dx.doi.org/10.2319/102911-668.1] [PMID: 22356706]
- [85] Yáñez-Vico RM, Iglesias-Linares A, Torres-Lagares D, Gutiérrez-Pérez JL, Solano-Reina E. A new three-dimensional analysis of asymmetry for patients with craniofacial syndromes. *Oral Dis* 2013; 19(8): 755-62. [http://dx.doi.org/10.1111/odi.12059] [PMID: 23294171]
- [86] Sanders DA, Chandhoke TK, Uribe FA, Rigali PH, Nanda R. Quantification of skeletal asymmetries in normal adolescents: Cone-beam computed tomography analysis. *Prog Orthod* 2014; 15(1): 26. [http://dx.doi.org/10.1186/s40510-014-0026-0] [PMID: 24935152]
- [87] Nur RB, Çakan DG, Arun T. Evaluation of facial hard and soft tissue asymmetry using cone-beam computed tomography. *Am J Orthod Dentofacial Orthop* 2016; 149(2): 225-37. [http://dx.doi.org/10.1016/j.ajodo.2015.07.038] [PMID: 26827979]
- [88] Kamata H, Higashihori N, Fukuoka H, Shiga M, Kawamoto T, Moriyama K. Comprehending the three-dimensional mandibular

- morphology of facial asymmetry patients with mandibular prognathism. *Prog Orthod* 2017; 18(1): 43.
[http://dx.doi.org/10.1186/s40510-017-0197-6] [PMID: 29243002]
- [89] Economou S, Stoustrup P, Kristensen KD, *et al.* Evaluation of facial asymmetry in patients with juvenile idiopathic arthritis: Correlation between hard tissue and soft tissue landmarks. *Am J Orthod Dentofacial Orthop* 2018; 153(5): 662-672.e1.
[http://dx.doi.org/10.1016/j.ajodo.2017.08.022] [PMID: 29706214]
- [90] You KH, Kim KH, Lee KJ, Baik HS. Three-dimensional computed tomography analysis of mandibular morphology in patients with facial asymmetry and mandibular retrognathism. *Am J Orthod Dentofacial Orthop* 2018; 153(5): 685-91.
[http://dx.doi.org/10.1016/j.ajodo.2017.08.024] [PMID: 29706216]
- [91] Kwon SM, Baik HS, Jung HD, Jang W, Choi YJ. Diagnosis and surgical outcomes of facial asymmetry according to the occlusal cant and menton deviation. *J Oral Maxillofac Surg* 2019; 77(6): 1261-75.
[http://dx.doi.org/10.1016/j.joms.2019.01.028] [PMID: 30794815]
- [92] Cevidanees LH, Alhadidi A, Paniagua B, *et al.* Three-dimensional quantification of mandibular asymmetry through cone-beam computerized tomography. *Oral Surg Oral Med Oral Pathol Oral Radiol Endod* 2011; 111(6): 757-70.
[http://dx.doi.org/10.1016/j.tripleo.2011.02.002] [PMID: 21497527]
- [93] Verhoeven TJ, Coppen C, Barkhuysen R, *et al.* Three dimensional evaluation of facial asymmetry after mandibular reconstruction: Validation of a new method using stereophotogrammetry. *Int J Oral Maxillofac Implants* 2013; 42(1): 19-25.
[http://dx.doi.org/10.1016/j.ijom.2012.05.036] [PMID: 22939875]
- [94] Claes P, Walters M, Vandermeulen D, Clement JG. Spatially-dense 3D facial asymmetry assessment in both typical and disordered growth. *J Anat* 2011; 219(4): 444-55.
[http://dx.doi.org/10.1111/j.1469-7580.2011.01411.x] [PMID: 21740426]
- [95] Demant S, Hermann NV, Darvann TA, *et al.* 3D analysis of facial asymmetry in subjects with juvenile idiopathic arthritis. *Rheumatology (Oxford)* 2011; 50(3): 586-92.
[http://dx.doi.org/10.1093/rheumatology/keq329] [PMID: 21097878]
- [96] Taylor HO, Morrison CS, Linden O, *et al.* Quantitative facial asymmetry: Using three-dimensional photogrammetry to measure baseline facial surface symmetry. *J Craniofac Surg* 2014; 25(1): 124-8.
[http://dx.doi.org/10.1097/SCS.0b013e3182a2e99d] [PMID: 24406564]
- [97] Wermker K, Kleinheinz J, Jung S, Dirksen D. Soft tissue response and facial symmetry after orthognathic surgery. *J Craniomaxillofac Surg* 2014; 42(6): e339-45.
[http://dx.doi.org/10.1016/j.jcms.2014.01.032] [PMID: 24406564]
- [98] Patel A, Islam SM, Murray K, Goonewardene MS. Facial asymmetry assessment in adults using three-dimensional surface imaging. *Prog Orthod* 2015; 16: 36.
[http://dx.doi.org/10.1186/s40510-015-0106-9] [PMID: 26490376]
- [99] Verhoeven T, Xi T, Schreurs R, Bergé S, Maal T. Quantification of facial asymmetry: A comparative study of landmark-based and surface-based registrations. *J Craniomaxillofac Surg* 2016; 44(9): 1131-6.
[http://dx.doi.org/10.1016/j.jcms.2016.07.017] [PMID: 27519663]
- [100] Kornreich D, Mitchell AA, Webb BD, Cristian I, Jabs EW. Quantitative assessment of facial asymmetry using three-dimensional surface imaging in adults: Validating the precision and repeatability of a global approach. *Cleft Palate Craniofac J* 2016; 53(1): 126-31.
[http://dx.doi.org/10.1597/13-353] [PMID: 25489769]
- [101] Codari M, Pucciarelli V, Stangoni F, *et al.* Facial thirds-based evaluation of facial asymmetry using stereophotogrammetric devices: Application to facial palsy subjects. *J Craniomaxillofac Surg* 2017; 45(1): 76-81.
[http://dx.doi.org/10.1016/j.jcms.2016.11.003] [PMID: 27939040]
- [102] Cassi D, Battistoni G, Magnifico M, Di Blasio C, Pedrazzi G, Di Blasio A. Three-dimensional evaluation of facial asymmetry in patients with hemifacial microsomia using stereophotogrammetry. *J Craniomaxillofac Surg* 2019; 47(1): 179-84.
[http://dx.doi.org/10.1016/j.jcms.2018.11.011] [PMID: 30527381]
- [103] Al-Rudainy D, Ju X, Stanton S, Mehendale FV, Ayoub A. Assessment of regional asymmetry of the face before and after surgical correction of unilateral cleft lip. *J Craniomaxillofac Surg* 2018; 46(6): 974-8.
[http://dx.doi.org/10.1016/j.jcms.2018.03.023] [PMID: 29752048]
- [104] Primožic J, Perinetti G, Zhurov A, Richmond S, Ovsenik M. Assessment of facial asymmetry in growing subjects with a three-dimensional laser scanning system. *Orthod Craniofac Res* 2012; 15(4): 237-44.
[http://dx.doi.org/10.1111/j.1601-6343.2012.01550.x] [PMID: 23020694]
- [105] Djordjevic J, Pirttiniemi P, Harila V, *et al.* Three-dimensional longitudinal assessment of facial symmetry in adolescents. *Eur J Orthod* 2013; 35(2): 143-51.
[http://dx.doi.org/10.1093/ejo/cjr006] [PMID: 21300725]
- [106] Djordjevic J, Toma AM, Zhurov AI, Richmond S. Three-dimensional quantification of facial symmetry in adolescents using laser surface scanning. *Eur J Orthod* 2014; 36(2): 125-32.
[http://dx.doi.org/10.1093/ejo/cjr091] [PMID: 21795753]
- [107] Ozsoy U. Comparison of different calculation methods used to analyze facial soft tissue asymmetry: Global and partial 3-dimensional quantitative evaluation of healthy subjects. *J Oral Maxillofac Surg* 2016; 74(9): 1847.e1-9.
[http://dx.doi.org/10.1016/j.joms.2016.05.012] [PMID: 27292525]
- [108] Ekrami O, Claes P, White JD, Zaidi AA, Shriver MD, Van Dongen S. Measuring asymmetry from high-density 3D surface scans: An application to human faces. *PLoS One* 2018; 13(12): e0207895
[http://dx.doi.org/10.1371/journal.pone.0207895] [PMID: 30586353]
- [109] Baik HS, Kim SY. Facial soft-tissue changes in skeletal Class III orthognathic surgery patients analyzed with 3-dimensional laser scanning. *Am J Orthod Dentofacial Orthop* 2010; 138(2): 167-78.
[http://dx.doi.org/10.1016/j.ajodo.2010.02.022] [PMID: 20691358]
- [110] Hartmann J, Meyer-Marcotty P, Benz M, Häusler G, Stellzig-Eisenhauer A. Reliability of a method for computing facial symmetry plane and degree of asymmetry based on 3D-data. *J Orofac Orthop* 2007; 68(6): 477-90.
[http://dx.doi.org/10.1007/s00056-007-0652-y] [PMID: 18034288]
- [111] Ostwald J, Berssenbrügge P, Dirksen D, *et al.* Measured symmetry of facial 3D shape and perceived facial symmetry and attractiveness before and after orthognathic surgery. *J Craniomaxillofac Surg* 2015; 43(4): 521-7.
[http://dx.doi.org/10.1016/j.jcms.2015.03.003] [PMID: 25841308]
- [112] Berssenbrügge P, Berlin NF, Kebeck G, *et al.* 2D and 3D analysis methods of facial asymmetry in comparison. *J Craniomaxillofac Surg* 2014; 42(6): e327-34.
[http://dx.doi.org/10.1016/j.jcms.2014.01.028] [PMID: 24507934]
- [113] Huang CS, Liu XQ, Chen YR. Facial asymmetry index in normal young adults. *Orthod Craniofac Res* 2013; 16(2): 97-104.
[http://dx.doi.org/10.1111/ocr.12010] [PMID: 23324075]
- [114] Hood CA, Bock M, Hosey MT, Bowman A, Ayoub AF. Facial asymmetry--3D assessment of infants with cleft lip & palate. *Int J Paediatr Dent* 2003; 13(6): 404-10.
[http://dx.doi.org/10.1046/j.1365-263X.2003.00496.x] [PMID: 14984046]
- [115] Shaner DJ, Peterson AE, Beattie OB, Bamforth JS. Assessment of soft tissue facial asymmetry in medically normal and syndrome-affected individuals by analysis of landmarks and measurements. *Am J Med Genet* 2000; 93(2): 143-54.
[http://dx.doi.org/10.1002/1096-8628(20000717)93:2<143::AID-AJMG12>3.0.CO;2-Q] [PMID: 10869118]
- [116] O'Grady KF, Antonyshyn OM. Facial asymmetry: Three-dimensional analysis using laser surface scanning. *Plast Reconstr Surg* 1999; 104(4): 928-37.
[http://dx.doi.org/10.1097/00006534-199909040-00006] [PMID: 10654730]
- [117] Hennessy RJ, McLearn S, Kinsella A, Waddington JL. Facial shape and asymmetry by three-dimensional laser surface scanning covary with cognition in a sexually dimorphic manner. *J Neuropsychiatry Clin Neurosci* 2006; 18(1): 73-80.
[http://dx.doi.org/10.1176/jnp.18.1.73] [PMID: 16525073]
- [118] Alqattan M, Djordjevic J, Zhurov AI, Richmond S. Comparison between landmark and surface-based three-dimensional analyses of facial asymmetry in adults. *Eur J Orthod* 2015; 37(1): 1-12.
[http://dx.doi.org/10.1093/ejo/cjt075] [PMID: 24152377]
- [119] Nkenke E, Lehner B, Kramer M, *et al.* Determination of facial symmetry in unilateral cleft lip and palate patients from three-dimensional data: Technical report and assessment of measurement errors. *Cleft Palate Craniofac J* 2006; 43(2): 129-37.
[http://dx.doi.org/10.1597/04-138.1] [PMID: 16526915]
- [120] Bilwatsch S, Kramer M, Haeusler G, *et al.* Nasolabial symmetry following Tennison-Randall lip repair: A three-dimensional approach in 10-year-old patients with unilateral clefts of lip, alveolus and palate. *J Craniomaxillofac Surg* 2006; 34(5): 253-62.
[http://dx.doi.org/10.1016/j.jcms.2006.03.001] [PMID: 16777429]
- [121] Stauber I, Vairaktaris E, Holst A, *et al.* Three-dimensional analysis of facial symmetry in cleft lip and palate patients using optical surface

- data. *J Orofac Orthop* 2008; 69(4): 268-82.
[<http://dx.doi.org/10.1007/s00056-008-0746-1>] [PMID: 18797831]
- [122] Damstra J, Fourie Z, De Wit M, Ren Y. A three-dimensional comparison of a morphometric and conventional cephalometric midsagittal planes for craniofacial asymmetry. *Clin Oral Investig* 2012; 16(1): 285-94.
[<http://dx.doi.org/10.1007/s00784-011-0512-4>] [PMID: 21271348]
- [123] Ferrario VF, Sforza C, Tartaglia GM, Sozzi D, Carù A. Three-dimensional lip morphometry in adults operated on for cleft lip and palate. *Plast Reconstr Surg* 2003; 111(7): 2149-56.
[<http://dx.doi.org/10.1097/01.PRS.0000060107.43208.21>] [PMID: 12794454]
- [124] Federici Canova F, Oliva G, Beretta M, Dalessandri D. Digital (R)Evolution: Open-source softwares for orthodontics. *Appl Sci (Basel)* 2021; 11(13): 6033.
[<http://dx.doi.org/10.3390/app11136033>]

© 2024 The Author(s). Published by Bentham Open.



This is an open access article distributed under the terms of the Creative Commons Attribution 4.0 International Public License (CC-BY 4.0), a copy of which is available at: <https://creativecommons.org/licenses/by/4.0/legalcode>. This license permits unrestricted use, distribution, and reproduction in any medium, provided the original author and source are credited.