



# The Open Dentistry Journal

Content list available at: <https://opendentistryjournal.com>



## CASE REPORT

### Gingival Squamous Cell Carcinoma Masquerading as Localized Periodontal Disease in the Maxilla: A Case Report

Elnaz Jalali<sup>1</sup>, Jyoti Mago<sup>2,\*</sup> and Aditya Tadinada<sup>3</sup>

<sup>1</sup>Department of Oral and Maxillofacial Radiology, Oral and Maxillofacial Radiology Practice, Dallas, Texas

<sup>2</sup>Department of Oral and Maxillofacial Radiology, University of Nevada, Las Vegas, NV 89154, USA

<sup>3</sup>School of Dental Medicine, University of Connecticut, Farmington, CT 06030, USA

#### Abstract:

#### Objectives:

Squamous cell carcinoma is a malignant neoplasm of epithelium. In the U.S., carcinoma of the gingiva constitutes 4% to 16% of all oral carcinomas. This case report highlights such a case in maxillary gingiva and emphasizes the vital role of dental professionals, especially periodontists and endodontists, in being cognizant that an inflammatory lesion can mimic a serious condition like squamous cell carcinoma.

#### Case Presentation:

A patient who visited the screening clinic for an ulcerated lesion in the gingiva was otherwise healthy with no associated history of tobacco or any traumatic/persistent traumatic events.

The patient was treated for pseudoepitheliomatous hyperplasia based on the current condition and negative history of malignancy. On three months of follow-up, computed tomography radiographic evaluation and a biopsy were done, which were positive for the malignancy. Follow-up after six months includes PET, Head MRI, and chest X-ray examinations to rule out any metastatic entity.

#### Results:

A six-month follow-up radiographic examination revealed metastasis of the entity. Additional findings include pleural effusion and underlying infections.

#### Conclusion:

Early diagnosis is the key to the treatment plan. It further highlights the role of advanced imaging as a vital tool in determining the extent of the disease. Therefore, any persistent lesion exhibiting features that are not responding to conventional gingival and periodontal treatment options for more than two weeks should be referred for further evaluation to rule out cancer.

**Keywords:** Gingiva, Squamous cell, Carcinoma, Periodontal disease, Mimic, Gum.

#### Article History

Received: July 24, 2021

Revised: October 11, 2021

Accepted: November 10, 2021

## 1. INTRODUCTION

Amongst the wide spectrum of pathological conditions encountered in the oral cavity, several conditions mimic each other and put the clinician at a diagnostic crossroad that can be very daunting. This is particularly true when the treatment is significantly different for each of the conditions on the differential diagnosis list. One such challenging conundrum is a similarity in the presentation of some inflammatory condi-

tions that can mimic malignant conditions and vice versa. Several times gingival squamous cell carcinoma can mimic localized periodontal disease and is often misdiagnosed and mismanaged. The diagnosis of gingival squamous cell carcinoma (SCC) is critical because of the time-sensitive nature of the condition. Accurate diagnosis is vital as tumor size and invasion into the surrounding anatomical structures and timely intervention decides the prognosis [1, 2].

Gingival squamous cell carcinoma often presents with benign features, and if misdiagnosed or not diagnosed in the early stages, it can lead to a delay in executing the appropriate

\* Address correspondence to this author at the Department of Oral and Maxillofacial Radiology, University of Nevada, Las Vegas, NV 89154, USA; E-mail: [jyoti.mago@unlv.edu](mailto:jyoti.mago@unlv.edu)

treatment. Gingival squamous cell carcinoma is often asymptomatic, and initial symptoms are usually an intraoral mass or swelling, ulceration, pain, ill-fitting dentures, mobility of teeth, or unhealed extraction wounds [3 - 5]. Computerized tomography (CT) and magnetic resonance imaging (MRI) are useful for evaluating the extent of carcinoma in the head and neck. This study highlights the clinical-histopathological and radiographic findings of a case of gingival SCC.

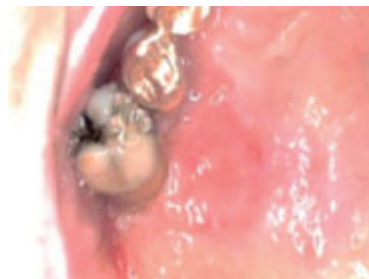## 2. CASE DESCRIPTION

### 2.1. Patient Information and Relevant History

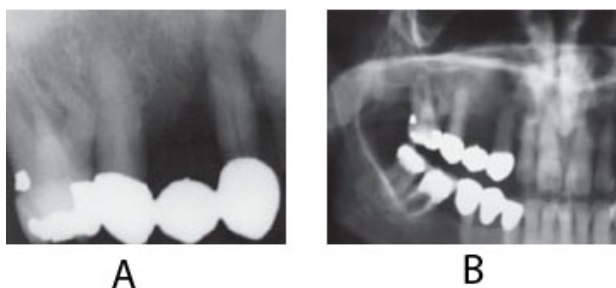
A 50-year-old male patient presented to a private dental office with the chief complaint of a lesion in the gums below heavily restored right maxillary first molar and second premolar. The patient was otherwise healthy with no history of tobacco use or any traumatic event.

### 2.2. Clinical Findings, Radiographic Findings, and Management

On clinical examination, an ulcerated lesion in the gingiva was present in the right posterior maxillary region (Fig. 1). Periapical and panoramic radiographs were done to evaluate the lesion further. Radiographic examinations revealed alveolar bone loss around the right maxillary first molar and second premolar and the canine, but the generalized alveolar bone loss was noted, with several other teeth in the oral cavity. Change in the trabecular pattern was observed in this area but was deemed to be the result of inflammation and possible infection (Fig. 2). Based on these findings, it was diagnosed as localized chronic severe periodontitis.



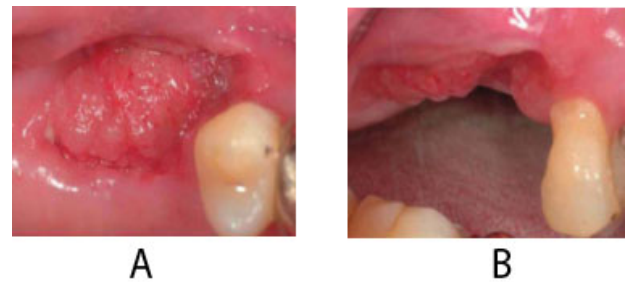**Fig. (1).** Clinical photograph showing the erythematous and ulcerative palatal gingiva.



**Fig. (2).** Periapical and panoramic films demonstrating advanced alveolar bone loss surrounding the dentition, as well as displacement of the right maxillary first molar. The alveolar bone destruction of the right maxillary first molar appeared as an ill-defined, non-corticated

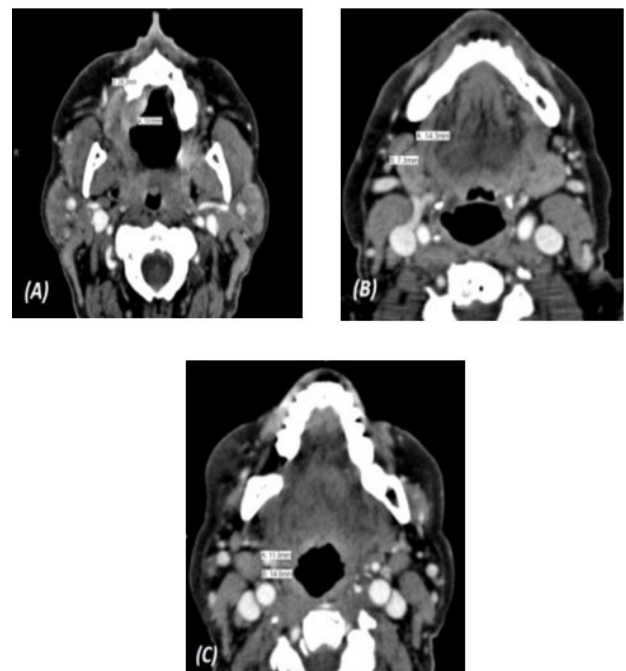
border, and the PDL associated with the tooth could not be visualized.

With the right maxillary first molar showing prognosis, the tooth was extracted. At a follow-up visit after three months, the lesion did not resolve after dental extraction and antibiotic therapy. Moreover, three months post-extraction, the mass showed rolled and raised borders (Fig. 3).

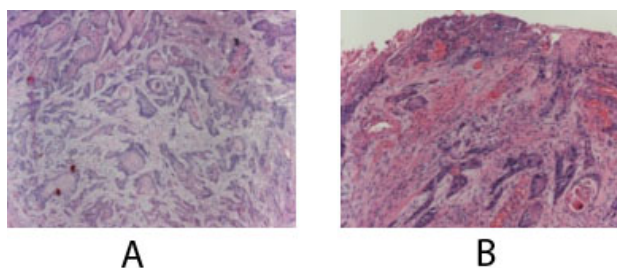


**Fig. (3).** Clinical presentation three months post-extraction. The mass exhibited rolled and raised borders.

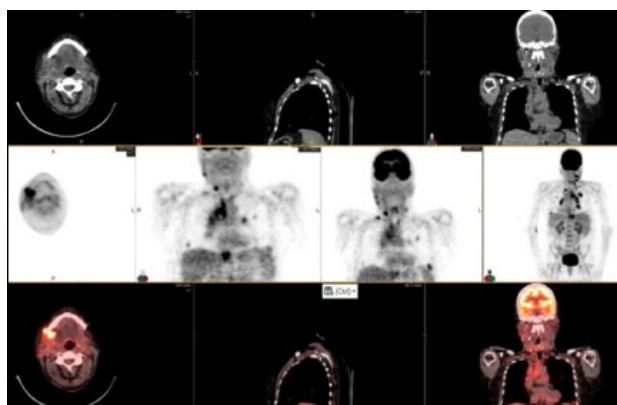
At this time, the case was referred to the University Hospital, and a computerized tomography scan (CT) was done to evaluate the lesion further. CT scan revealed an enhancing soft tissue mass in the right gingiva destroying the palate and causing irregular thinning of maxilla and adjacent maxillary sinus wall. The scan also showed enlargement of the lymph nodes (Fig. 4). Subsequent histology confirmed the diagnosis of a well-differentiated squamous cell carcinoma SCC (Fig. 5).



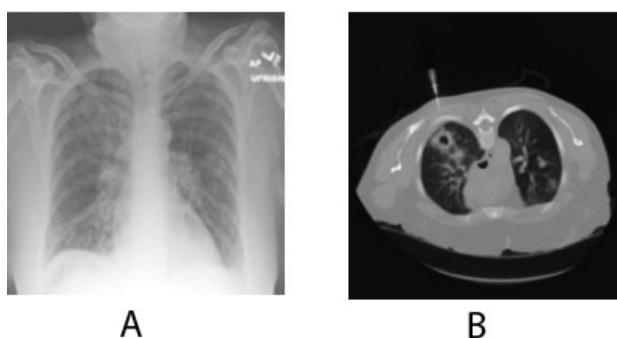**Fig. (4).** A) Axial CT, soft tissue window showing an enhancing soft tissue mass in the region of the right gingiva extending medially to the level of the roof of the mouth. B) Mildly enlarged lymph node anterior to the right submandibular gland, and C) Another mildly prominent jugulodigastric lymph node.



**Fig. (5).** Invasive squamous cell carcinoma within the sub mucosa. High power view of the ulcerated surface from which nests of infiltrative squamous cell carcinoma arise. Nests infiltrate the superficial lamina propria with abundant keratin pearls.



**Fig. (6).** There are focal areas of avid activity at the level of the mandible on the right juxtaposition to the operative site, as well as focal areas of metabolic activity in the region of the submandibular gland corresponding to a lymph node, at the level of cricoid cartilage posterior to SCM and lateral to the jugular vein which corresponds to a lymph node, and areas of metabolic activity within the lung parenchyma.



**Fig. (7).** AP chest x-ray showing multiple ill-defined nodular densities in the lungs consistent with known metastases to the lungs. A guided lung biopsy of a dominant opacity in the right upper lobe.

The patient eventually underwent multiple resections of the maxilla at the initial site of the mass and multiple neck dissection surgeries for the next six months. The biopsy results repeatedly revealed metastatic disease spreading to the lower neck lymph nodes. Positron Emission Tomography (PET/CT) scan result showed increased metabolic activity posterior to the

sternocleidomastoid, contralateral neck, and within the lung parenchyma (Fig. 6). Head MRI was performed to detect metastatic spread to the brain and maxillofacial regions and showed no focal mass, abnormal enhancement, midline shift, or acute intracranial hemorrhage. A chest x-ray confirmed metastasis to the lungs (Fig. 7). To this date, the patient's condition is worsening with progressive metastasis, pleural effusion, and underlying infections.

### 3. DISCUSSION

Gingival squamous cell carcinoma accounts for less than 10% of all oral cancers [6]. It is mainly reported in the elderly, with about 2% of the patient population reporting less than 40 years of age [7]. Gingival carcinomas are usually squamous cell carcinomas that are typically well-differentiated [8]. It is predominant in males. Carcinoma of the gingiva is insidious in growth and painless. One common finding is that in its early stages, it is often misdiagnosed as inflammatory lesions of the periodontium, such as pyogenic granuloma, periodontitis, papilloma, or even fibroid epulis (inflammatory hyperplasia) [8]. As in our study, the lesion mimicked localized chronic severe periodontitis and possibly a pseudoepitheliomatous hyperplasia.

Most gingival squamous cell carcinomas are found in the mandible. Interestingly, in this case, it was in the maxilla. The site of the mass is very important as it is vital for the identification of the spaces and location of tumor spread. A schematic diagram of the tumor spread in the maxilla and mandible is described in Fig. (8). Cady *et al.*, in 1969, did a 20-year survey on epidermoid carcinoma of the gum and found that posterior lesions tend to be larger with involvement of bone and other adjacent structures [9]. In this case, too, the initial lesion was in the posterior maxilla. This suggests the pivotal role of advanced imaging in appropriate diagnosis, delineating the extent and possible spread of the disease.

While evaluating the extent, the buccal and gingival areas of the lesion should be carefully evaluated for the extent of submucosal spread, osseous involvement, involvement of the retromolar trigone, pterygomandibular raphe, and cervical lymphatic spread [10]. The presence of osseous involvement is suggestive of a T4 lesion. The staging of the disease is important both for the treatment and prognosis.

Computed tomography (CT) is excellent at showing the subtle cortical erosions, and the extent of marrow involvement may be better assessed by using magnetic resonance (MR) imaging. CT findings of osseous involvement include cortical erosion surrounding the primary lesion, aggressive periosteal reaction, abnormal attenuation in bone marrow, and pathologic fractures [11]. In this case presentation, CT findings revealed osseous involvement and nodal involvement of Level I and II. Since nodal involvement is the single most important prognostic indicator, an accurate assessment of all nodal chains at the same time is essential in staging, treatment, and prognosis (Table 1). Hence, advanced imaging is key in detecting the prognosis of the disease.

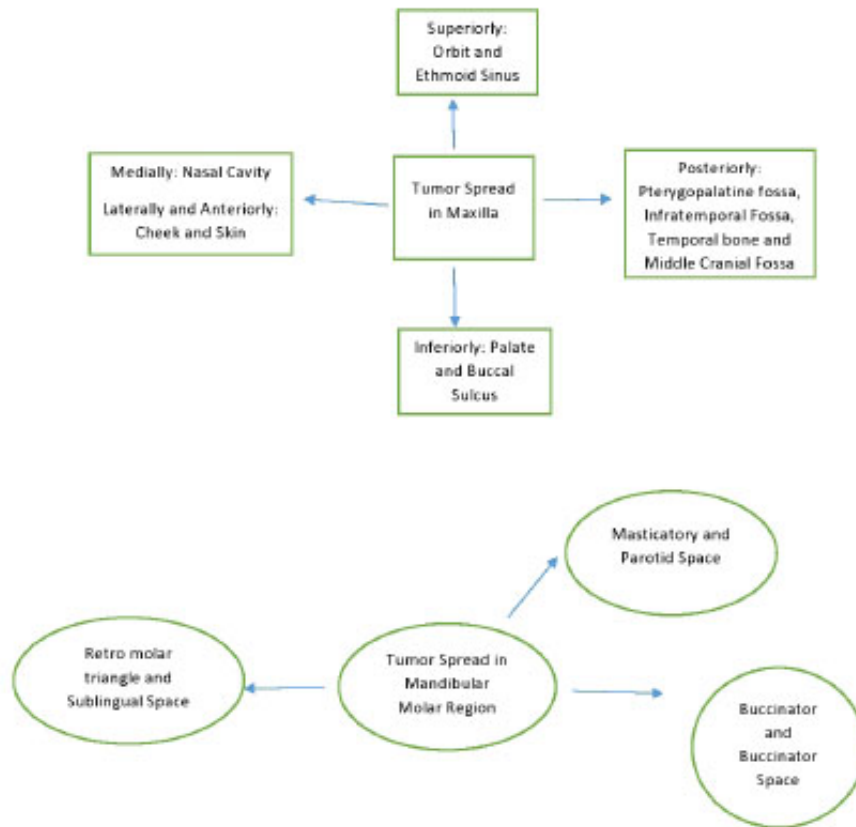


Fig. (8). Schematic representation of the spread of tumor in maxilla and mandible.

Table 1. Levels of lymph nodes.

| Level of Lymph Nodes | Anatomical Location   |
|----------------------|---|
| I                    | All nodes above the hyoid bone, below the mylohyoid muscle, and anterior to a transverse line drawn on each axial image through the posterior edge of the submandibular gland.  |
| II                   | Skull base, at the lower level of the bony margin of the jugular fossa, to the level of the lower body of the hyoid bone.   |
| III                  | Between the level of the lower body of the hyoid bone and the level of the lower margin of the cricoid cartilage arch.  |
| IV                   | Between the level of the lower margin of the cricoid cartilage arch and the level of the clavicle on each side as seen on each axial scan.  |
| V                    | Skull base, at the posterior border of the attachment of the sternocleidomastoid muscle, to the level of the clavicle as seen on each axial scan.   |
| VI                   | Inferior to the lower body of the hyoid bone, superior to the top of the manubrium, and between the medial margins of the left and right common carotid arteries or the internal carotid arteries. They are the visceral nodes. |
| VII                  | Caudal to the top of the manubrium in the superior mediastinum, between the medial margins of the left and right common carotid arteries.   |

MR imaging findings that are indicative of osseous involvement include loss of low-signal-intensity cortex, replacement of high signal intensity marrow on T1-weighted images by intermediate-signal-intensity tumor, contrast enhancement within the bone, and contrast enhancement of nerves traversing the mandible. In our study, a Head MRI was performed to evaluate the area, but no concurrent findings were noted.

Lubek *et al.* in 2011, conducted a retrospective analysis of 72 patients with gingival carcinoma and indications for elective

neck dissection. They found that elective neck dissection is indicated for all stages of mandibular gingival and T3 or T4 carcinomas of the maxillary gingiva. T2 maxillary SCC should be considered for neck dissection. Overall, disease-free survival was worse among those with cervical metastasis and patients who had marginal resections [11]. In this case, neck dissections were performed but leading up to the current time in the patient’s follow-up, the patient did not respond well to any therapy. Hence, it is noteworthy that conditions like this must be diagnosed as early as possible. Therefore, any persistent lesion exhibiting features that are not responding to



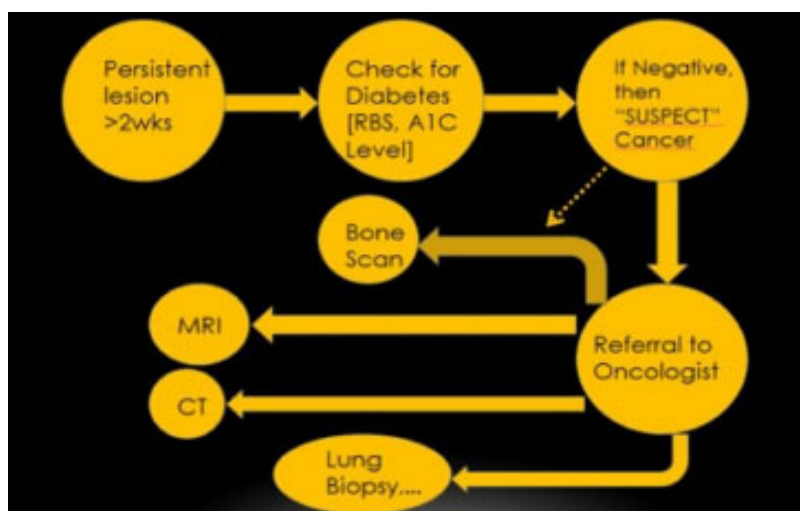


Fig. (9). Flowchart of diagnostic decision.

conventional gingival and periodontal treatment options for more than two weeks should be referred for further evaluation to rule out cancer (Fig. 9). The 5-year survival rate of gingival SCC is considerably less when compared to SCC developing at other sites, suggesting a poor prognosis [12].

This case highlights the presence of a very serious condition like gingival squamous cell carcinoma (SCC) and its deceptive behavior as a benign and inflammation-mimicking lesion in the gingiva. Many times, clinicians dismiss persistent lesions as idiopathic without adequate investigations, and doing so could result in missing a potentially life-threatening disease like squamous cell carcinoma (SCC).

## CONCLUSION

This case report emphasizes that clinicians should pay attention to unresolving lesions, especially those of inflammatory origin, and serves as a reminder that delay in appropriate radiographic examination and diagnosis of these lesions may adversely affect the prognosis.

## AUTHORS' CONTRIBUTION

Data acquisition and analysis of data were performed by Dr. Elnaz Jalali. Dr. Jyoti Mago wrote the manuscript and is the corresponding author. Dr. Aditya Tadinada is the guarantor who edited the manuscript and reviewed it.

## ETHICS APPROVAL AND CONSENT TO PARTICIPATE

This study was approved by the Hanoi National Hospital of Odonto Stomatology, Vietnam (No. 217/HDDD-BVRHMTW).

## HUMAN AND ANIMAL RIGHTS

No animals were used in this research. All human research procedures were followed in accordance with the ethical standards of the committee responsible for human experimentation (institutional and national), and with the Helsinki Declaration of 1975, as revised in 2013.

## CONSENT FOR PUBLICATION

Informed consent was obtained from patients and their parents for treatment and publication.

## STANDARDS OF REPORTING

CARE guidelines and methodologies were followed in this study.

## AVAILABILITY OF DATA AND MATERIALS

The data supporting findings of this study is available from the corresponding author [J.M.], upon reasonable request.

## FUNDING

None.

## CONFLICT OF INTEREST

The authors declare no conflict of interest, financial or otherwise.

## ACKNOWLEDGEMENTS

Declared none.

## REFERENCES

- [1] Overholt SM, Eicher SA, Wolf P, Weber RS. Prognostic factors affecting outcome in lower gingival carcinoma. *Laryngoscope* 1996; 106(11): 1335-9. [http://dx.doi.org/10.1097/00005537-199611000-00006] [PMID: 8914897]
- [2] Hirai T, Korogi Y, Hamatake S, *et al.* Stages III and IV squamous cell carcinoma of the mouth: three-year experience with superselective intraarterial chemotherapy using cisplatin prior to definitive treatment. *Cardiovasc Intervent Radiol* 1999; 22(3): 201-5. [http://dx.doi.org/10.1007/s002709900366] [PMID: 10382049]
- [3] Gomez D, Faucher A, Picot V, *et al.* Outcome of squamous cell carcinoma of the gingiva: a follow-up study of 83 cases. *J Craniomaxillofac Surg* 2000; 28(6): 331-5. [http://dx.doi.org/10.1054/jcms.2000.0177] [PMID: 11465139]
- [4] Palme CE, Gullane PJ, Gilbert RW. Current treatment options in squamous cell carcinoma of the oral cavity. *Surg Oncol Clin N Am* 2004; 13(1): 47-70. [http://dx.doi.org/10.1016/S1055-3207(03)00123-6] [PMID: 15062361]
- [5] Shingaki S, Nomura T, Takada M, Kobayashi T, Suzuki I, Nakajima

- T. Squamous cell carcinomas of the mandibular alveolus: Analysis of prognostic factors. *Oncology* 2002; 62(1): 17-24. [http://dx.doi.org/10.1159/000048242] [PMID: 11810039]
- [6] Smoker WRK. Oral cavity. In: Som PM, Curtin HD, Eds. *Head and Neck Imaging*. 3<sup>rd</sup> ed. St Louis, Mo: Mosby 1996; pp. 488-544.
- [7] Hollows P, McAndrew PG, Perini MG. Delays in the referral and treatment of oral squamous cell carcinoma. *Br Dent J* 2000; 188(5): 262-5. [http://dx.doi.org/10.1038/sj.bdj.4800449] [PMID: 10758688]
- [8] McClatchy KD, Zarbo RJ. *The jaws and oral cavity. Diagnostic Surgical Pathology*. 3<sup>rd</sup> ed. Philadelphia: Lippincott Williams and Wilkins 1999; p. 822.
- [9] Cady B, Catlin D. Epidermoid carcinoma of the gum. A 20-year survey. *Cancer* 1969; 23(3): 551-69. [http://dx.doi.org/10.1002/1097-0142(196903)23:3<551::AID-CNCR2820230306>3.0.CO;2-K] [PMID: 5766499]
- [10] Trotta BM, Pease CS, Rasamny JJ, Raghavan P, Mukherjee S. Oral cavity and oropharyngeal squamous cell cancer: key imaging findings for staging and treatment planning. *Radiographics* 2011; 31(2): 339-54. [http://dx.doi.org/10.1148/rg.312105107] [PMID: 21415183]
- [11] Lubek J, El-Hakim M, Salama AR, Liu X, Ord RA. Gingival carcinoma: retrospective analysis of 72 patients and indications for elective neck dissection. *Br J Oral Maxillofac Surg* 2011; 49(3): 182-5. [http://dx.doi.org/10.1016/j.bjoms.2010.04.005] [PMID: 20462676]
- [12] O'Sullivan B, Shah J. New TNM staging criteria for head and neck tumors. *Semin Surg Oncol* 2003; 21(1): 30-42. [http://dx.doi.org/10.1002/ssu.10019] [PMID: 12923914]

© 2024 The Author(s). Published by Bentham Open.



This is an open access article distributed under the terms of the Creative Commons Attribution 4.0 International Public License (CC-BY 4.0), a copy of which is available at: <https://creativecommons.org/licenses/by/4.0/legalcode>. This license permits unrestricted use, distribution, and reproduction in any medium, provided the original author and source are credited.