

# Properties of *Citrullus Colocynthis* as a Pulpotomy Medicament: An Animal Study



Elahe Tahmasebi<sup>1</sup>, Kiyavash Raeisolvaezin<sup>2</sup>, Mohsen Yazdanian<sup>1</sup>, Samira Hajisadeghi<sup>1,\*</sup> and Reza Mirnejad<sup>3</sup>

<sup>1</sup>Research Center for Prevention of Oral and Dental Diseases, Baqiyatallah University of Medical Sciences, Tehran, Iran

<sup>2</sup>Traditional and Complementary Medicine Research Center, Arak University of Medical Sciences, Arak, Iran

<sup>3</sup>Molecular Biology Research Center, Systems Biology and Poisoning Institute, Baqiyatallah University of Medical Sciences, Tehran, Iran

## Abstract:

**Introduction:** As the carcinogenic properties of formocresol spark global concern, the exploration of safer alternatives becomes paramount in pediatric dentistry. This study assesses the efficacy of *Citrullus colocynthis* extract, recognized for its potent anti-inflammatory and antimicrobial qualities, as a potential substitute in pulpotomy treatments.

**Methods and Materials:** Employing a controlled experimental design, eight New Zealand white rabbits underwent pulpotomy using either the traditional formocresol or the novel *Citrullus colocynthis* extract. Following the treatments, comprehensive histological assessments were performed to evaluate inflammatory responses, tissue necrosis, and morphological changes in pulp cells. Data analysis was conducted with SPSS, utilizing Chi-square and Mann Whitney tests to ascertain statistical significance.

**Results:** Statistically significant disparities were evident in the levels of inflammation, infiltration of inflammatory cells, and morphological changes of pulp tissue cells, with the *Citrullus colocynthis* extract group showing more pronounced adverse effects. In contrast, rates of necrosis did not differ significantly between the two groups.

**Conclusion:** Despite its notable anti-inflammatory properties, *Citrullus colocynthis* extract induced significant adverse cellular reactions in pulpotomy applications. While promising as a therapeutic agent, its potential cellular toxicity suggests a cautious approach to clinical usage in dental treatments, warranting further investigation and optimization for safety.

**Keywords:** *Citrullus colocynthis*, Pulpotomy, Herbal medicament, Herbal extract, Pediatric dentistry, Antimicrobial qualities.

© 2025 The Author(s). Published by Bentham Open.

This is an open access article distributed under the terms of the Creative Commons Attribution 4.0 International Public License (CC-BY 4.0), a copy of which is available at: <https://creativecommons.org/licenses/by/4.0/legalcode>. This license permits unrestricted use, distribution, and reproduction in any medium, provided the original author and source are credited.

\*Address correspondence to this author at the Research Center for Prevention of Oral and Dental Diseases, School of dentistry, Baqiyatallah University of Medical Sciences, Sheikhabahaei Street, Tehran, Iran; Postal code: 1435814717; Tel: +989126806435; E-mail: [dr.s.hajisadeghi@gmail.com](mailto:dr.s.hajisadeghi@gmail.com)

Cite as: Tahmasebi E, Raeisolvaezin K, Yazdanian M, Hajisadeghi S, Mirnejad R. Properties of *Citrullus Colocynthis* as a Pulpotomy Medicament: An Animal Study. Open Dent J, 2025; 19: e18742106356123. <http://dx.doi.org/10.2174/0118742106356123250212111254>



CrossMark

Received: September 06, 2024

Revised: December 05, 2024

Accepted: December 11, 2024

Published: February 25, 2025



Send Orders for Reprints to  
[reprints@benthamscience.net](mailto:reprints@benthamscience.net)

## 1. INTRODUCTION

Tooth decay is a pervasive chronic infectious disease that is both treatable and preventable [1]. Treatment of primary tooth caries varies depending on its extent and the presented signs and symptoms, necessitating diverse dental interventions. Preserving primary teeth in a healthy functional state is crucial for maintaining not only arch length but also a child's aesthetic appearance, mastication, speech, and oral-facial development. Therefore, the principal aim of pediatric dentistry is to uphold arch space by retaining natural deciduous teeth until the eruption of their permanent successors [2, 3].

Long-standing research by dental scholars has focused on treating pulp diseases and exposures in primary and young permanent teeth, whether due to decay or trauma. The quest for the ideal medicament to cover the exposed pulp post-treatment has long been a matter of debate [4]. Pulpotomy, the procedure that entails the coronal pulp's removal, aims to preserve the vitality of the tooth and promote pulp healing. The overarching goal of pulpal therapy in children is to ensure the health and function of deciduous teeth until permanent ones emerge [5, 6].

The history of pulpotomy dates back to 1904, when Buckley introduced formocresol, which was later popularized by Sweet in 1930 as a pulpotomy technique for primary teeth [7]. However, concerns have risen since the International Agency for Research on Cancer classified formaldehyde, a component of formocresol, as a carcinogen linked to leukemia and nasopharyngeal carcinoma in 2004 [8]. Despite the clinical efficacy of formocresol, its potential for causing sensitization, cytotoxicity, mutagenicity, carcinogenicity, and harmful fetal effects has driven researchers to seek safer alternatives. In this quest, medicinal plant extracts have garnered attention due to their safety, natural composition, and affordability [9-11].

The use of medicinal plants in healthcare, disease prevention, and treatment has significantly increased globally over the years. These plants are not only dietary staples and primary materials but are also reservoirs of diverse chemicals and natural molecules that have catalyzed the development of various medications [12]. The desert plant *Citrullus colocynthis*, known for its myriad bioactive compounds—fatty acids, glycosides, flavonoids, alkaloids, and essential oils—has been extensively studied for its antibacterial, antioxidant, and anti-inflammatory properties, leading to its use in addressing diabetes, inflammation, parasitic infections, and cancer [13].

*Citrullus colocynthis*, commonly known for its extensive medicinal applications, has demonstrated significant antimicrobial properties. Research shows that extracts from the fruit and seeds of *C. colocynthis* are effective against both gram positive and gram negative bacteria, including *Escherichia coli*, *Pseudomonas aeruginosa*, *Staphylococcus aureus*, and *Enterococcus faecalis* [14, 15]. These findings underscore its potential as an alternative to traditional antimicrobials in treating bacterial infections.

In traditional medicine, *C. colocynthis* has been valued for its efficacy in treating a range of disorders, from digestive issues to chronic diseases. It is notably used for indigestion, gastroenteritis, diabetes, and liver problems, as well as for relieving pain due to its analgesic properties [16, 17]. Additionally, it is applied in the management of respiratory and gastrointestinal ailments like colds, diarrhea, and bronchitis and is also used for reducing fever [18].

The multifaceted efficacy of *Citrullus colocynthis* not only highlights its potential as a comprehensive therapeutic agent but also underscores the importance of further research to unlock its full potential in clinical settings, particularly in pulpotomy and other dental applications. The promising results suggest a pathway for its integration into modern medical practices, albeit with careful consideration of its dosage and toxicity to optimize safety and effectiveness. References to the efficacy of *Citrullus colocynthis* and its extract for toothache relief are noted in the traditional medicinal teachings of Iran and Pakistan. Considering the extensive research on pulpotomy-related properties of various traditionally used plants and the recognized antimicrobial and anti-inflammatory qualities of *Citrullus colocynthis*, this study aims to investigate the effectiveness of its ethanol extract in animal models for pulpotomy treatment [16, 19, 20].

## 2. METHODS AND MATERIALS

This study was conducted adhering to ethical guidelines for laboratory research, with a commitment to environmental preservation and humane treatment of animals. Ethical approval was obtained from the Baqiyatallah University of Medical Sciences' ethical committee [Ethics Code: IR.BMSU.BAQ.REC.1398.057] prior to the initiation of research activities.

### 2.1. Plant Extraction Process

The *Citrullus colocynthis* plants used in our study were obtained from the Medicinal Plants and Drugs Research Institute of Shahid Beheshti University. Further information about the institute can be found on their official website: <https://mpdri.sbu.ac.ir/>. The process began with the drying of *Citrullus colocynthis* fruits under shade. To prepare the ethanolic extract, 400 grams of these dried fruits were ground and macerated in a 70:30 ethanol-water solution, totaling 1.2 liters, for three days. The solution was stirred twice for optimal extraction. Post-maceration, the solution was filtered three times. After the ethanol was evaporated using a rotary evaporator, the remaining water was separated through lyophilization, and the freeze-dried extract was obtained [21, 22].

### 2.2. Animal Intervention

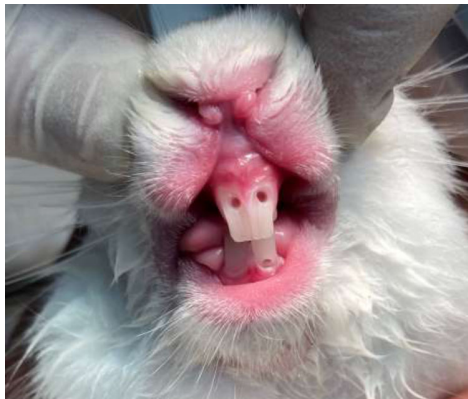
The rabbits used in our study were purchased by the Animal Center of Baqiyatallah University of Medical Sciences from the Pasteur Institute of Iran. Below are the relevant details:

Supplier Name: Pasteur Institute of Iran, Address: No. 69, Pasteur Ave, Tehran, Iran

Eight male New Zealand White rabbits, aged  $14.4 \pm 2.1$  weeks and weighing  $2 \text{ kg} \pm 200 \text{ g}$ , were used in this study. The rabbits were housed in individual steel cages within a sterile room at the Animal Center of Baqiyatallah University of Medical Sciences. The environmental conditions were carefully controlled, maintaining a temperature of  $24^\circ\text{C} \pm 2^\circ\text{C}$ , relative humidity of 60%, light intensity of 350–400 lux, noise levels below 85 dB, and a 12-hour light/dark cycle. The animals were acclimatized to these conditions for three days before cavity preparation and for eight days before euthanasia.

The rabbits were provided with unlimited access to dried food pellets (*Witte Molen*, Netherlands) and fresh water. All procedures were conducted in accordance with the ethical approval obtained for the study.

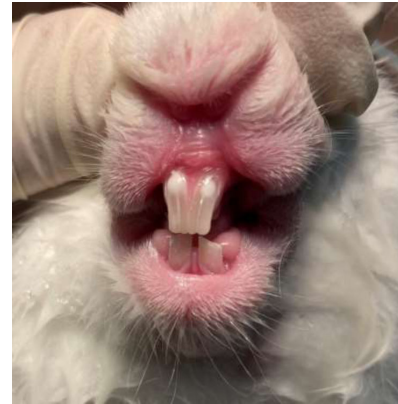
For anesthesia, a combination of ketamine (35 mg/kg) and xylazine (5 mg/kg) was administered intramuscularly. Following anesthesia, the anterior maxillary and mandibular regions were disinfected with a 2% chlorhexidine solution. Using a sterile high-speed handpiece and a round diamond bur, access cavities were created on the buccal surfaces of the central incisors [23, 24]. Pulp tissue removal was meticulously performed using a sterile spoon excavator. Hemostasis was achieved with sterile cotton balls moistened with saline (Fig. 1). A simple randomisation method was used to allocate teeth to treatment groups. A random number generator was employed to assign one tooth per rabbit to the formocresol group, while the remaining teeth were assigned to the *Citrullus colocynthis* extract group. This ensured the unbiased allocation of treatments across the samples. Through this process, the teeth were chosen to receive either formocresol or *Citrullus colocynthis* extract, applied via cotton balls for five minutes. Depending on the rabbits' cooperation and the effective duration of anesthesia, 2–3 teeth per rabbit were treated.



**Fig. (1).** Preparation of access cavities on central incisors and hemostasis.

After the application of either formocresol or the *Citrullus colocynthis* extract, a zinc oxide mixture was applied to the cavities. For teeth treated with formocresol, the mixture consisted of zinc oxide and eugenol, whereas for those treated with the *Citrullus colocynthis* extract, a

mixture of zinc oxide and the extract was used. Following this, the access cavities were sealed using a self-cured restorative glass ionomer (Fig. 2).



**Fig. (2).** Restoring access cavities with glass ionomer.

Eight days following the treatment, the rabbits were euthanized using a triple dose of the anesthetic. The absence of any signs of vitality was confirmed, ensuring a humane endpoint before the sampling of the upper and lower jaws based on the teeth that received treatment [24].

### 2.3. Histological Examination

After the teeth were fixed in a 10% formaldehyde solution, they were sent to the laboratory. The process for preparing the samples for microscopic examination included decalcification in a 20% formic acid solution buffered with sodium citrate for ten days, longitudinal sectioning, dehydration, and embedding in paraffin. Following these steps, the samples were stained using the hematoxylin and eosin (H&E) method. This series of steps culminated in the preparation of slides for microscopic analysis. The histological findings are illustrated in Figs. (3–5).

Upon preparation, the slides underwent examination by a histopathologist under a microscope. The evaluation focused on:

#### 2.3.1. Inflammation

Characterized by the dilation of blood vessels and an increase in interstitial fluid.

#### 2.3.2. Necrosis

Identified by the amount and expansion of the area of necrotic cells.

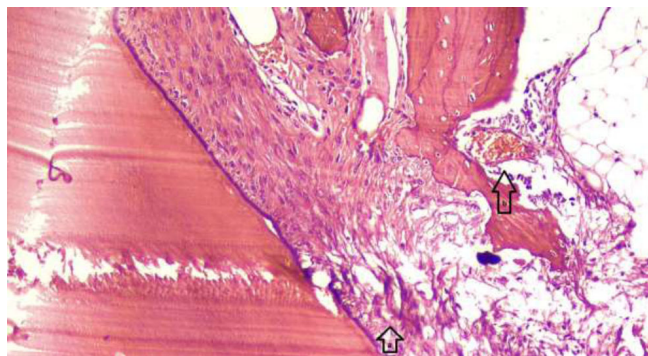
#### 2.3.3. Infiltration of Inflammatory Cells

Primarily measured by the presence of macrophages within the tissue.

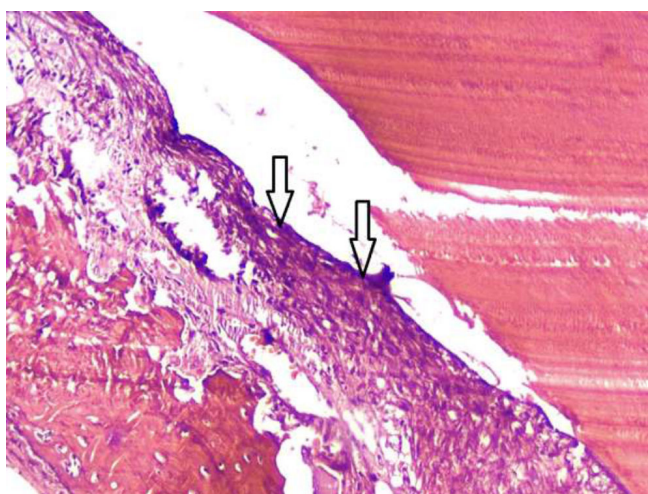
#### 2.3.4. Morphological Change of Cells

Observed as alterations in the appearance and structure of cells present in the pulp tissue.





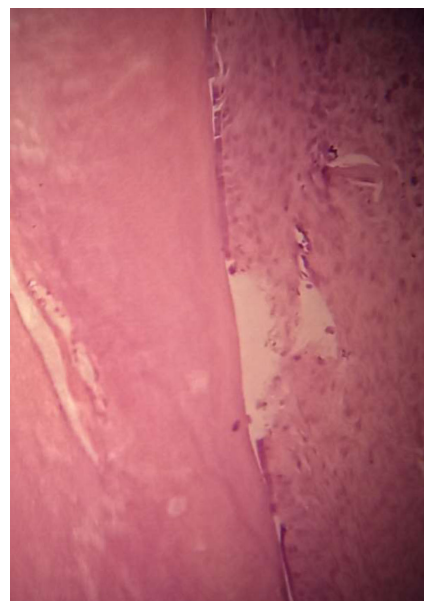
**Fig. (3).** Histological image of a rabbit tooth treated with *Citrullus colocynthis* extract, showing localized morphological changes in pulp tissue and mild inflammation. (a) Arrows indicating localized morphological changes of pulp cells, with evidence of cell distortion and altered cell arrangement. (b) Dilation of blood vessels in response to inflammation, as marked by arrows, indicating increased vascularity in the affected area. The changes observed suggest a response to the treatment, with possible localized inflammation. Hematoxylin and eosin staining is shown with 100x magnification.



**Fig. (4).** Histological image of a rabbit tooth treated with *Citrullus colocynthis* extract, showing the onset of localized necrosis. Arrows indicating the initial area of necrosis, where the pulp tissue begins to lose its normal structure. The necrotic region is still localized but has the potential to spread due to the extent of tissue damage. The affected area exhibits signs of cell death, with the absence of viable cells in the region. Hematoxylin and eosin staining is shown with 100x magnification.

The histopathologist conducted a qualitative assessment, categorizing the presence of inflammation and the infiltration of inflammatory cells as negative, low, moderate, or high, and assigned a rating from 0 to +3 based on the intensity and spread of the inflammation. Similarly, the assessment of necrosis and morphological changes in tissue was reported as negative, low and limited, or high and widespread, rated from 0 to +2.

It is important to note that not all pathological symptoms (*e.g.*, inflammation, necrosis, morphological changes) may be visible in a single section of the tooth, as these changes can be focal and may occur at varying distances from the site of treatment. Therefore, the pathologist thoroughly examined all sections of each treated tooth to ensure comprehensive evaluation. Each section was scored individually, with the cumulative findings used to assess the overall response to treatment. This approach ensures that localized changes, which may not be present in every section, are adequately captured and considered in the final analysis.



**Fig. (5).** Histological image of a rabbit tooth treated with formocresol, showing no signs of inflammation or other adverse effects in this section. The pulp tissue appears healthy, with normal cellular architecture and no observable changes in morphology or vascular dilation. Hematoxylin and eosin staining is shown with 40x magnification.

## 2.4. Statistical Analysis

Data were analyzed using Chi-square and Mann-Whitney tests through SPSS software (version 26), with a significance threshold set at  $p < 0.05$ . This approach facilitated a comparative analysis between the effects of formocresol and *Citrullus colocynthis* extract.

## 3. RESULTS

### 3.1. Inflammation

Only 2 of the 7 samples treated with formocresol (28.6%) showed mild inflammation, while the other 5 samples (71.4%) exhibited no inflammation. In contrast, among the 13 samples treated with *Citrullus colocynthis* extract, 4 had no inflammation, 2 displayed mild inflammation, 4 had moderate inflammation, and 3 showed severe inflammation under microscopic examination (Table 1).

**Table 1. Comparison of inflammation between the groups and the result of statistical analysis.**

-			Inflammation				-	Chi2
			Negative	1+	2+	3+	Mann-Whitney	
Medicament	F.	Count	5	2	0	0	0.032	0.029
		Percent	71.4%	28.6%	0.0%	0.0%		
	C.c.	Count	4	2	4	3		
		Percent	30.75%	15.4%	30.75%	23.1%		

Abbreviations: (F.: Formocresol, C.c.: *Citrullus colocynthis*).**Table 2. Comparison of necrosis between the groups and the result of statistical analysis.**

-			Necrosis			-	Chi2
			Negative	1+	2+	Mann-Whitney	
Medicament	F.	Count	5	2	0	0.101	0.09
		Percent	71.4%	28.6%	0.0%		
	C.c.	Count	5	4	4		
		Percent	38.5%	30.75%	30.75%		

Abbreviations: (F.: Formocresol, C.c.: *Citrullus colocynthis*).

### 3.2. Necrosis

Of the 7 cases treated with formocresol, 2 (28.6%) showed local necrosis, while no necrosis was observed in the remaining cases. In the samples treated with *Citrullus colocynthis* extract, out of 13, there were 4 instances of local necrosis, 4 of diffuse necrosis, and 5 with no tissue necrosis reported (Table 2).

### 3.3. Infiltration of Inflammatory Cells

This study focused mainly on the infiltration of macrophages. Only 1 of the 7 cases treated with formocresol

(14.3%) showed mild infiltration, with the remaining 6 being negative. Among the cases treated with *Citrullus colocynthis* extract, out of 13, 5 were negative, 5 showed mild infiltration, 2 displayed moderate infiltration, and 1 case showed widespread infiltration of inflammatory cells (Table 3).

### 3.4. Morphological Change of Pulp Tissue

No morphological changes in pulp tissue cells were observed in any of the samples treated with formocresol. In comparison, among the 13 cases treated with *Citrullus colocynthis* extract, 3 showed severe morphological changes, 5 had mild changes, and 5 showed no changes (Table 4).

**Table 3. Comparison of infiltration of inflammatory cells between the groups and the result of statistical analysis.**

-			Inflammatory Cell Infiltration				-	Chi2
			Neg.	1+	2+	3+	Mann-Whitney	
Medicament	F.	Count	6	1	0	0	0.043	0.05
		Percent	85.7%	14.3%	0.0%	0.0%		
	C.c.	Count	5	5	2	1		
		Percent	38.5%	38.5%	15.4%	7.6%		

Abbreviations: (F.: Formocresol, C.c.: *Citrullus colocynthis*).**Table 4. Comparison of morphological change of pulp tissue between the groups and the result of statistical analysis.**

-			Morphologic Change			-	Chi2
			Neg.	1+	2+	Mann-Whitney	
Medicament	F.	Count	7	0	0	0.011	0.017
		Percent	100.0%	0.0%	0.0%		
	C.c.	Count	5	5	3		
		Percent	38.5%	38.5%	23%		

Abbreviations: (F.: Formocresol, C.c.: *Citrullus colocynthis*).

Based on the available findings and statistical tests, there were statistically significant differences between the two groups treated with *Citrullus colocynthis* extract and formocresol in terms of inflammation, infiltration of

inflammatory cells, and morphological changes of pulp cells. However, no statistically significant difference was observed in the occurrence of necrosis between the two groups (Fig. 6).

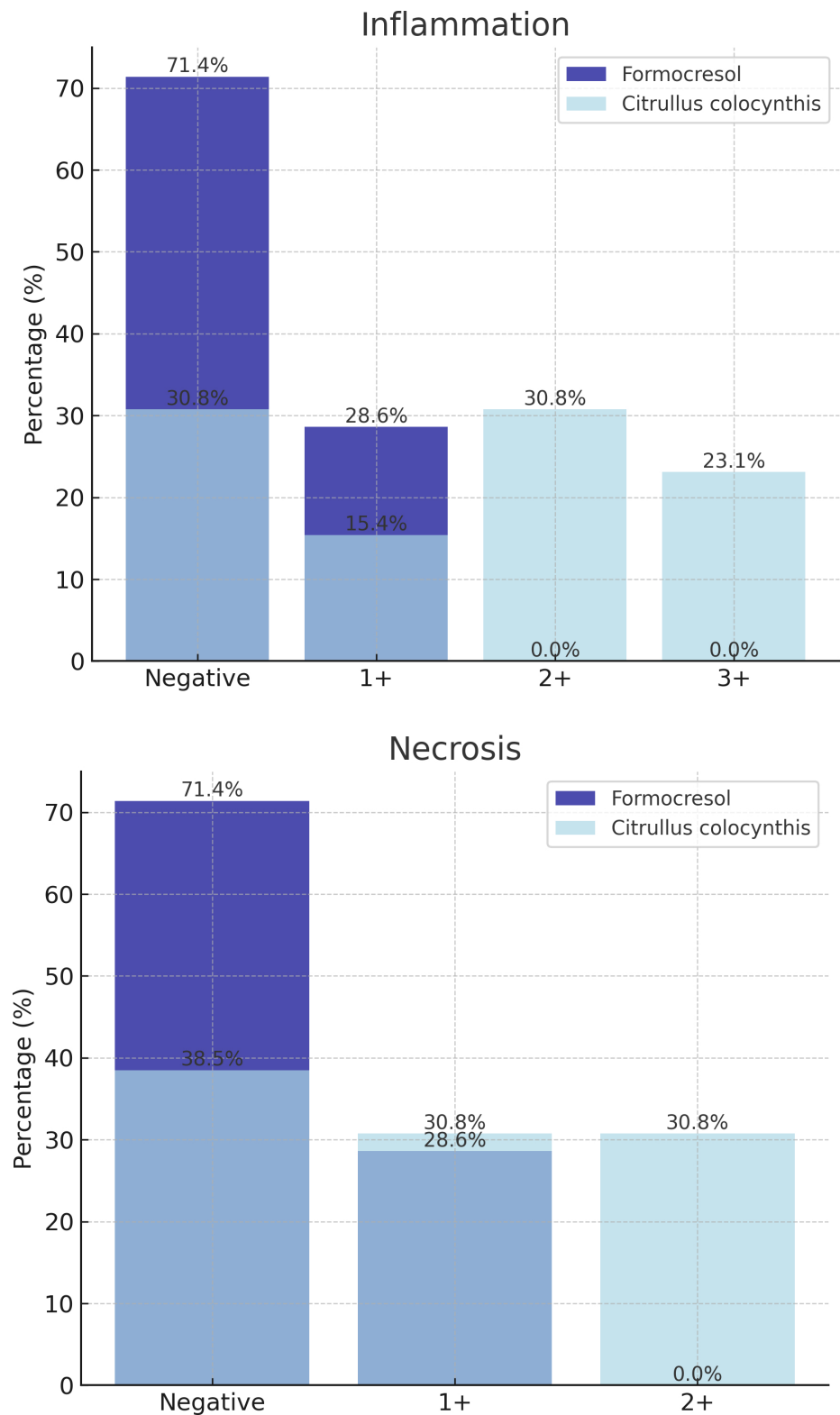
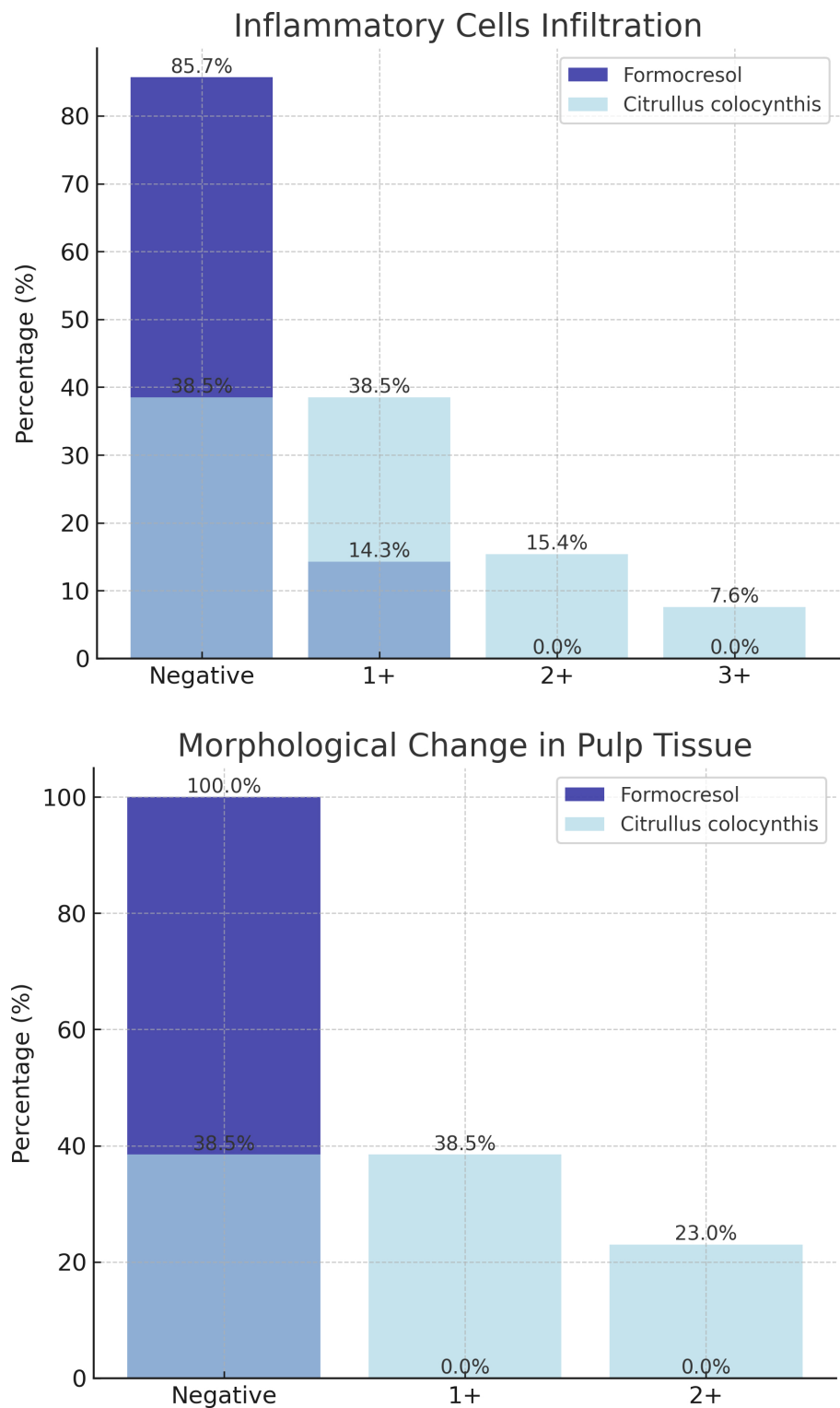


Fig. 6 contd.....



**Fig. (6).** Comparison between groups based on studied parameters.

**4. DISCUSSION**

Plants and naturally-derived substances have long been integral to traditional medicine, with a multitude of therapeutic applications derived from a wide range of

botanicals. The growing interest in plant-based medicines, especially as alternatives to synthetic antibiotics, emphasizes their potential importance. The fruit of *Citrullus colocynthis*, known for its anti-inflammatory and analgesic

properties, was evaluated in this study for its efficacy in pulpotomy treatments and its impact on pulp tissue cells. Contrary to expectations based on its established medicinal uses, our findings indicated significant adverse cellular reactions in pulpotomy applications, highlighting a discrepancy between general anti-inflammatory benefits and specific clinical outcomes in dental treatments.

In our animal study, after preparing slides and conducting histopathological examinations [as detailed in the results], we observed a notable difference between the two intervention groups treated with formocresol and *Citrullus colocynthis* extract in terms of inflammation, infiltration of inflammatory cells, and morphological changes in pulp tissue cells. However, no significant difference was noted in the extent of tissue necrosis. Importantly, necrosis in the formocresol group was localized and associated with tissue fixation near the substance, whereas in the *Citrullus colocynthis* extract group, widespread necrosis followed tissue damage and inflammation. Additionally, control teeth were examined to ensure no pre-existing inflammation or disease, confirming the health of the pulp tissue in these samples.

The selection of rabbits as our experimental model was driven by several considerations. Although the use of rabbits in pulp therapy research is less common than other animals like dogs, cats, pigs, and monkeys, they offer notable advantages due to their economical upkeep and shorter lifespan. Rabbit teeth, particularly incisors, are of a suitable size for testing restorative procedures. Despite their teeth's continuous growth and wear, the results from applying pulp therapy materials on rabbit incisors align well with findings from numerous *in vivo* and *in vitro* studies, suggesting their suitability for short-term evaluations of new dental materials [25-29]. In a similar vein, Kayad *et al.* also utilized rabbit incisors in their study to evaluate dental materials, underscoring the methodological parallels between our approaches [24].

Exploring the antimicrobial efficacy of *Citrullus colocynthis*, studies by Barakian *et al.* and Tahmasebi *et al.* provide compelling insights. Barakian *et al.* focused on the ability of the extract to inhibit the growth of *Streptococcus mutans* and *Lactobacillus acidophilus*, pathogens associated with dental caries, without showing bactericidal properties [30]. Tahmasebi *et al.* extended this examination to include both antibacterial and antifungal properties against a broader spectrum of pathogens, demonstrating significant inhibitory and lethal effects [31]. While both studies confirm the broad-spectrum antimicrobial potential of *Citrullus colocynthis*, our research raises concerns about its direct application in pulpotomy due to observed adverse cellular responses, suggesting a discrepancy between antimicrobial efficacy and biocompatibility in direct pulp contact.

Similarly, Ghahramani *et al.* compared the antibacterial effectiveness of *Citrullus colocynthis* extract to calcium hydroxide against *Enterococcus faecalis*, finding the plant extract's performance commendable over a two-week period, with effects comparable to the traditional endodontic medicament [32]. This comparison under-

scores the potential of *Citrullus colocynthis* in microbial management but contrasts with the adverse effects observed in our pulpotomy study, highlighting the complexity of its clinical application.

Moreover, research by Alofi *et al.* [33], which evaluates other natural substances in dental treatments [such as propolis and garden thyme], highlights both the potential and limits of using natural extracts. These studies provide a broader context within which our findings can be understood, suggesting that while natural substances like *Citrullus colocynthis* can offer significant benefits, their clinical application must be carefully evaluated to prevent adverse outcomes. This nuanced approach emphasizes the necessity for meticulous evaluation and optimization of natural extracts to ensure their efficacy and safety in clinical settings.

The study by Dehghani *et al.* on the toxicological effects of *Citrullus colocynthis* extract on pregnant mice highlighted significant systemic toxicity at higher concentrations, revealing concerns about the potential adverse effects on fetal viability and maternal survival [34]. This study underscores the critical need for careful dose management and further toxicity evaluation when considering *Citrullus colocynthis* for clinical applications.

By examining these studies together with our findings, it becomes clear that while *Citrullus colocynthis* exhibits significant therapeutic potential, its application in dental treatments requires meticulous evaluation to balance antimicrobial benefits against possible adverse cellular responses. Further investigations are essential to delineate the mechanisms of action and to establish safe and effective protocols for its use in dental therapies.

## 5. METHODOLOGY LIMITATIONS AND FUTURE IMPROVEMENTS

This study, while providing valuable insights into the use of *Citrullus colocynthis* as a pulpotomy medicament, is not without limitations. First, the sample size was constrained due to financial limitations, which prevented us from acquiring additional rabbits for the study. The ethics committee, recognizing the novelty of the subject and the lack of existing evidence for the treatment, only approved the use of eight rabbits, which restricted the number of subjects available for analysis. This limitation in sample size must be considered when interpreting the results.

Second, the choice of incisor teeth instead of molars was driven by practical considerations. Incisors offer better access to treatment, especially within the short duration of anesthesia, which is a critical factor when working with animal models. Additionally, several studies on pulpotomy or direct pulp capping treatments in rabbits have used incisors due to their size and accessibility, making them a standard choice in dental research with similar models. While we recognize that molars might provide more direct comparisons to human teeth, incisors were deemed the most feasible option given the constraints of the study.



A third limitation was the absence of Immunohistochemistry (IHC) staining. Due to financial constraints, we were unable to include IHC staining, which could have provided more detailed insights into inflammation and apoptosis mechanisms in the treated tissues. Although IHC staining was not incorporated in this study, we believe it is an important method that could enhance future studies on this subject, especially for confirming the mechanisms of cellular changes induced by *Citrullus colocynthis*.

Another key issue was the control group design. In this study, each rabbit served as its own control, with one tooth randomly treated with formocresol, given its long-established use and high success rates. The decision to use only one formocresol-treated tooth was based on the historical reliability of the material and ethical considerations to minimize animal use. Unfortunately, one of the formocresol samples was lost during the tissue cutting and staining process. For the *Citrullus colocynthis* treatment, each rabbit was treated with one or two teeth, depending on the cooperation of the animal during anesthesia. The split-mouth design was implemented to maximize the number of teeth treated with the extract, which resulted in an unequal number of samples across the two groups. This design choice was made to optimize the potential findings and increase the data for the experimental group.

## CONCLUSION

Despite the antimicrobial properties and its ability to induce tissue necrosis, the ethanolic extract of *Citrullus colocynthis* is not recommended as a substitute for formocresol in pulpotomy treatments due to its high cellular toxicity. While it may alleviate acute symptoms in cases of severe pulpitis by inducing necrosis, its widespread necrotic effect and uncertain impact on surrounding tissues render its use inadvisable in these treatments.

## SUGGESTIONS FOR FUTURE STUDIES

Future work could focus on evaluating alternative herbal medicaments for pulpotomy, with larger sample sizes and more robust experimental designs. Further, incorporating advanced techniques, such as immunohistochemistry could provide deeper insights into the biological mechanisms involved in pulp tissue response.

## AUTHORS' CONTRIBUTIONS

E.T.: Study conception and design; K.R.: Investigation; M.Y.: Visualization; S.H.: Original draft preparation; R.M.: and writing, reviewing, and editing. All authors reviewed the results and approved the final version of the manuscript.

## LIST OF ABBREVIATIONS

C.c. / C.	= <i>Colocynthis Citrullus colocynthis</i>
F.	= Formocresol
SPSS	= Statistical Package for the Social Sciences

S. mutans	= <i>Streptococcus mutans</i>
S. salivarius	= <i>Streptococcus salivarius</i>
E. coli	= <i>Escherichia coli</i>
S. aureus	= <i>Staphylococcus aureus</i>
L. acidophilus	= <i>Lactobacillus acidophilus</i>
C. albicans	= <i>Candida albicans</i>
mg	= Milligram
kg	= Kilogram
ml	= Milliliter

## ETHICS APPROVAL AND CONSENT TO PARTICIPATE

Ethical approval was obtained from the Baqiyatallah University of Medical Sciences' ethical committee [Ethics Code: IR.BMSU.BAQ.REC.1398.057], Iran prior to the initiation of research activities.

## HUMAN AND ANIMAL RIGHTS

This study adheres to internationally accepted standards for animal research, following the 3Rs principle. The ARRIVE guidelines were employed for reporting experiments involving live animals, promoting ethical research practices. The animal experimentation was conducted according to the Guide for the Care and Use of Laboratory Animals.

## CONSENT FOR PUBLICATION

Not applicable.

## AVAILABILITY OF DATA AND MATERIALS

All data generated or analyzed during this study are included in this published article.

## FUNDING

None.

## CONFLICT OF INTEREST

The authors declare no conflict of interest, financial or otherwise.

## ACKNOWLEDGEMENTS

The authors wish to express their gratitude to Shokri Dental Hospital for providing the facilities necessary to conduct the animal studies involved in this research. Their support was instrumental in the completion of this work.

## REFERENCES

- [1] Krol DM, Nedley MP. Dental caries: State of the science for the most common chronic disease of childhood. *Adv Pediatr* 2007; 54(1): 215-39.  
<http://dx.doi.org/10.1016/j.yapd.2007.03.012> PMID: 17918473
- [2] Cohn C. Pulpotomy for primary teeth with tricalcium silicate material. *Inside Dentistry* 2013; 9(9): 7-11.
- [3] Godhi B, Sood PB, Sharma A. Effects of mineral trioxide aggregate and formocresol on vital pulp after pulpotomy of primary molars: An *in vivo* study. *Contemp Clin Dent* 2011; 2(4): 296-301.

- <http://dx.doi.org/10.4103/0976-237X.91792> PMID: 22346156
- [4] Ranly DM. Formocresol toxicity. Current knowledge. Acta Odontol Pediatr 1984; 5(2): 93-8. PMID: 6399663
  - [5] Howley B, Seale NS, McWhorter AG, Kerins C, Boozer KB, Lindsey D. Pulpotomy versus pulpectomy for carious vital primary incisors: Randomized controlled trial. Pediatr Dent 2012; 34(5): 112-9. PMID: 23211895
  - [6] Coll JA, Dhar V, Chen C-Y, et al. Use of vital pulp therapies in primary teeth 2024. Pediatr Dent 2024; 46(1): 13-26. PMID: 38449041
  - [7] Sweet CA. Procedure for treatment of exposed and pulpless deciduous teeth. J Amer Dent Assoc 1930; 17(6): 1150-3.
  - [8] Coglian VJ, Grosse Y, Baan RA, Straif K, Secretan MB, Ghissassi FE. Meeting report: Summary of IARC monographs on formaldehyde, 2-butoxyethanol, and 1-tert-butoxy-2-propanol. Environ Health Perspect 2005; 113(9): 1205-8. <http://dx.doi.org/10.1289/ehp.7542> PMID: 16140628
  - [9] Salman BN, Vahabi S, Rad MM. Use of herbs and medicinal plants in dentistry: A review. J Dental School 2017; 35(2): 58-64.
  - [10] Hussin NFM, Altarawneh HMD, Nik WNNW, Arzmi MH, Ismail A, Ghani ASM. Therapeutic effect of natural herbs in dentistry: A narrative review: Received 2024-02-21; Accepted 2024-03-04; Published 2024-03-25. Journal of Health and Translational Medicine (JUMMEC) 2024; pp. 187-203.
  - [11] Srinath S. Comparative evaluation of clinical and radiographic success of aloe-vera and formocresol pulpotomy in primary molars-A randomised control trial. RGUHS J Dental Sci 2022; 14(2): 54-60.
  - [12] Oncag O, Cogulu D, Uzel A, Sorkun K. Efficacy of propolis as an intracanal medicament against Enterococcus faecalis. Gen Dent 2006; 54(5): 319-22. PMID: 17004565
  - [13] Smet DP. Citrullus colocynthis Adverse effects of herbal drugs. Springer 1997; pp. 29-36. [http://dx.doi.org/10.1007/978-3-642-60367-9\\_4](http://dx.doi.org/10.1007/978-3-642-60367-9_4)
  - [14] Marzouk B, Marzouk Z, Décor R, et al. Antibacterial and anticandidal screening of Tunisian Citrullus colocynthis Schrad. from Medenine. J Ethnopharmacol 2009; 125(2): 344-9. <http://dx.doi.org/10.1016/j.jep.2009.04.025> PMID: 19397972
  - [15] Bourhia M, Bouothmany K, Bakrim H, et al. Chemical profiling, antioxidant, antiproliferative, and antibacterial potentials of chemically characterized extract of Citrullus colocynthis L. seeds. Separations 2021; 8(8): 114. <http://dx.doi.org/10.3390/separations8080114>
  - [16] Hussain AI, Rathore HA, Sattar MZA, Chatha SAS, Sarker SD, Gilani AH. Citrullus colocynthis (L.) Schrad (bitter apple fruit): A review of its phytochemistry, pharmacology, traditional uses and nutritional potential. J Ethnopharmacol 2014; 155(1): 54-66. <http://dx.doi.org/10.1016/j.jep.2014.06.011> PMID: 24936768
  - [17] Abdulridha MK, Marzoqi AAH, Ghasemian A. The anticancer efficiency of Citrullus colocynthis toward the colorectal cancer therapy. J Gastrointest Cancer 2020; 51(2): 439-44. <http://dx.doi.org/10.1007/s12029-019-00299-6> PMID: 31463888
  - [18] Rahimi R, Amin G, Ardekani MRS. A review on Citrullus colocynthis Schrad.: From traditional Iranian medicine to modern phytotherapy. J Altern Complement Med 2012; 18(6): 551-4. <http://dx.doi.org/10.1089/acm.2011.0297> PMID: 22784342
  - [19] Ilkhani R, Ghazimoradi Z. Extraction and classification of medical narratives of the book "Al-Kafi", according to authentication 2013.
  - [20] Huseini FH, Bahadori A, Nikkhah E, Ziaee M. Citrullus colocynthis (L.) Schrad: A promising prospect towards pharmacology, traditional uses, and potential applications. Biomed Res Bullet 2023; 1(2): 77-83. <http://dx.doi.org/10.34172/biomedrb.2023.14>
  - [21] Kouadri I, Satha H. Extraction and characterization of cellulose and cellulose nanofibers from Citrullus colocynthis seeds. Ind Crops Prod 2018; 124: 787-96. <http://dx.doi.org/10.1016/j.indcrop.2018.08.051>
  - [22] Ghauri AO, Ahmad S, Rehman T. In vitro and in vivo anti-diabetic activity of Citrullus colocynthis pulpy flesh with seeds hydro-ethanolic extract. J Complement Integr Med 2020; 17(2): 20180228. <http://dx.doi.org/10.1515/jcim-2018-0228> PMID: 31971913
  - [23] Likitpongpipat N, Sangmaneeet S, Klanrit P, Noisombut R, Krisanaprakornkit S, Chailertvanitkul P. Promotion of dental pulp wound healing in New Zealand white rabbits' teeth by Thai propolis product. J Vet Dent 2019; 36(1): 17-24. <http://dx.doi.org/10.1177/0898756418818891> PMID: 30587093
  - [24] Kayad M, Koura A, Nozahy EA. A comparative histological study of the effect of TheraCal LC and biodentine on direct pulp capping in rabbits: An experimental study. Clin Oral Investig 2022; 27(3): 1013-22. <http://dx.doi.org/10.1007/s00784-022-04658-9> PMID: 35947203
  - [25] Gandolfi MG, Siboni F, Prati C. Chemical-physical properties of TheraCal, a novel light-curable MTA-like material for pulp capping. Int Endod J 2012; 45(6): 571-9. <http://dx.doi.org/10.1111/j.1365-2591.2012.02013.x> PMID: 22469093
  - [26] Peskersoy C, Lukarcanin J, Turkun M. Efficacy of different calcium silicate materials as pulp-capping agents: Randomized clinical trial. J Dent Sci 2021; 16(2): 723-31. <http://dx.doi.org/10.1016/j.jds.2020.08.016> PMID: 33854725
  - [27] Natale LC, Rodrigues MC, Xavier TA, Simões A, Souza dDN, Braga RR. Ion release and mechanical properties of calcium silicate and calcium hydroxide materials used for pulp capping. Int Endod J 2015; 48(1): 89-94. <http://dx.doi.org/10.1111/iej.12281> PMID: 24646329
  - [28] Rossi DA, Silva LAB, Hernández GP, et al. Comparison of pulpal responses to pulpotomy and pulp capping with biodentine and mineral trioxide aggregate in dogs. J Endod 2014; 40(9): 1362-9. <http://dx.doi.org/10.1016/j.joen.2014.02.006> PMID: 25146016
  - [29] Rutherford RB, Spångberg L, Tucker M, Rueger D, Charette M. The time-course of the induction of reparative dentine formation in monkeys by recombinant human osteogenic protein-1. Arch Oral Biol 1994; 39(10): 833-8. [http://dx.doi.org/10.1016/0003-9969\(94\)90014-0](http://dx.doi.org/10.1016/0003-9969(94)90014-0) PMID: 7741652
  - [30] Barakian Q. In vitro study on antibacterial effect of aqueous and alcoholic extract of Citrullus colocynthis fruit on Streptococcus mutans and Lactobacillus acidophilus. Journal of Mashhad Dental School 2022; 46(1): 17-24.
  - [31] Tahmasebi E, Yazdani M, Tebyaniyan H, Soudi A, Ranjbar R, Moghaddam MM, et al. The antifungal and antibacterial effect of citrullus colocynthis: In vitro study. Open Access Maced J Med Sci 2022; 10(A): 1585-91.
  - [32] Ghahramani Y, Mohammadi N, Baghaei S, Jahandizi GN. Time-dependent antibacterial effects of citrullus colocynthis seed extract compared to calcium hydroxide in teeth infected with enterococcus faecalis. J Dent 2023; 25: 77.
  - [33] Alolofi H, Sayed EM, Taha S. Clinical and radiographical evaluation of propolis and thymus vulgaris extracts compared with formocresol pulpotomy in human primary molars. BDJ Open 2016; 2(1): 16005. <http://dx.doi.org/10.1038/bdjopen.2016.5> PMID: 29607066
  - [34] Dehghani F. Toxic effects of hydroalcoholic extract of Citrullus colocynthis on pregnant mice. J Iran Veterin Res 2008; 9(1): 42-5.